

Contents

Foreword

Preface

Chapter 1

Chapter 2

Chapter 3

Chapter 4

Chapter 5

Chapter 6

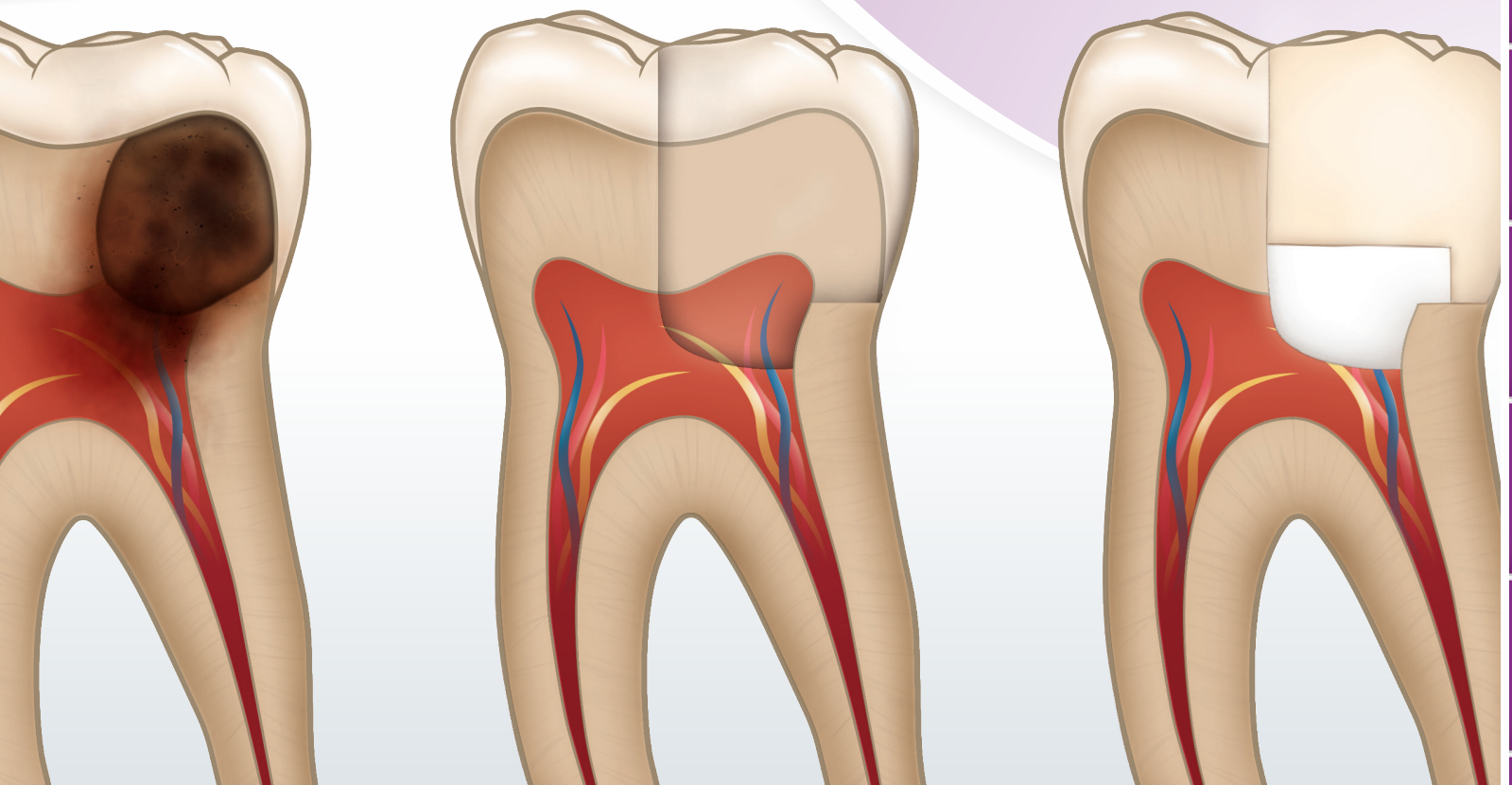
Chapter 7

Chapter 8

Chapter 9



A guide to  
**Good  
Endodontic  
Practice**



# A guide to Good Endodontic Practice

Edited by Phillip L Tomson

First edition published September 2022

Published by British Endodontic Society (UK) London

[www.britishendodonticsociety.org.uk](http://www.britishendodonticsociety.org.uk)

---

©British Endodontic Society (UK) 2022 All rights reserved. While every effort has been made to ensure the accuracy of the information contained in this publication, no guarantee can be given that all errors and omissions have been excluded. The British Endodontic Society (UK) can accept no responsibility for loss occasioned to any person acting or refraining from action as a result of material in this publication.

# CONTRIBUTORS

## Editor

**Phillip L Tomson** BDS PhD MFDS RCS (Ed) RCS (Eng) FDS (Rest Dent) RCS (Ed)  
Senior Clinical Lecturer and Hon. Consultant in Restorative Dentistry  
Head of Endodontics  
University of Birmingham / Birmingham Community Healthcare NHS Foundation Trust

## Contributors

**Noman Athwal** BDS MSc  
Dentist with practice limited to Endodontics  
Private practice

**Sanjeev Bhandari** BDS MSc FDS RCPS(Glasg) F.CGDent  
Specialist Endodontist, Endo 61, Cheshire  
Senior Lecturer, University of Liverpool

**Maria Lessani** BDS MFDS RCPS MCLinDent MRD RCS  
Specialist Endodontist, Endoclinic, Cockfosters, Hertfordshire  
Senior Clinical Teaching Fellow, Eastman Dental Institute, University College London

**Alyn Morgan** BChD MSc MFDTEd  
Specialist Endodontist, U Dentistry, Valley Drive, Ilkley, West Yorkshire  
Senior Clinical Teaching Fellow, Leeds Dental Institute

**Pratik Kamalkant Shah** BDS MFDS RCS (Ed) MSc M Endo RCS (Ed) FHEA  
Clinical Lecturer in Endodontics  
Barts and The London School of Medicine and Dentistry, Queen Mary University of London

BES council has made a tremendous contribution to this document by commissioning and supporting it throughout its development. Council members have given freely of their time to provide constructive feedback as it evolved. Particular thanks go to Raj Rattan MBE BDS FFGDP FICD FFFLM, Dental Director at Dental Protection for his contribution and imparting expertise and guidance from a medico-legal point of view.



# CONTENTS

Chapter		Page
	<b>Foreword</b> - Philip J Lumley	i
	<b>Preface</b> - Phillip L Tomson	ii
<b>1</b>	<b>Endodontic examination and diagnosis</b> Sanjeev Bhanderi	1
<b>2</b>	<b>Case difficulty assessment and knowing when to refer</b> Pratik Shah	14
<b>3</b>	<b>Good endodontic record keeping</b> Sanjeev Bhanderi	21
<b>4</b>	<b>Management of endodontic emergencies</b> Alyn Morgan	30
<b>5</b>	<b>Vital pulp therapy</b> Phillip L Tomson	36
<b>6</b>	<b>Primary root canal treatment</b> Phillip L Tomson and Noman Athwal	47
<b>7</b>	<b>Non-surgical retreatment</b> Pratik Shah	57
<b>8</b>	<b>Restoration of endodontically treated teeth</b> Phillip L Tomson	65
<b>9</b>	<b>Management of sodium hypochlorite accident</b> Maria Lessani	71

# FOREWORD

Promoting, educating and advancing Endodontics is central to the charitable work of the British Endodontic Society. It is both a pleasure and an honour to be asked to write a foreword to the British Endodontic Society Guidelines on Good Endodontic Practice. This guidance is timely as we emerge from the Covid pandemic with the demand for endodontic care never being greater regardless of which area of dentistry we work in.

The practice of endodontics has changed greatly over my career. When I look back at the first cases I treated nearly 45 years ago the principles remain very much the same, however the armamentarium we have available to us now has made good endodontic treatment more accessible than ever.

This guidance reviews those basic principles and takes the reader through the decision making process that leads to an endodontic intervention. A framework is then outlined addressing the different stages of treatment, including, most importantly, thorough bio-mechanical management of the root canal system and restoration of the endodontically treated tooth.

I congratulate those members of the British Endodontic Society who have contributed to this work under the editorship of Dr Phil Tomson. I hope and believe it will prove a useful reference for all members of the dental profession for students through to advanced practitioners.

## Professor Philip J Lumley

Professor of Endodontics and Hon. Consultant in Restorative Dentistry  
Deputy Head of College of Medical and Dental Sciences  
University of Birmingham/Birmingham Community Healthcare NHS Foundation Trust

# ■ PREFACE

I am delighted to welcome readers to the first edition of "A guide to Good Endodontic Practice" (GEP) developed by the British Endodontic Society (BES) to support the work of the organisation in promoting and advancing the discipline of Endodontics.

Pulpal and periradicular diseases are common and can cause significant morbidity. This guide has been developed in an easily digestible and accessible format to help support all levels of practitioners by providing a framework and a set of standards to work to in order to deliver good endodontic care. From examination and diagnosis, through execution of treatment to subsequent restoration of the endodontically treated tooth, this document guides the reader through the various stages of endodontic case management. The guide incorporates a broad range of topics including case difficulty assessment (featuring the use of the BES EndoApp), record keeping, management of endodontic emergencies and the management of sodium hypochlorite accidents. There is also particular emphasis on the evolving area of vital pulp therapy.

It must be acknowledged that this guide is not the first such document to be produced by the BES. "Guidelines for root canal treatment" (BES 1983) were developed by a working party which included Jack Rowe, Chris Stock, Karen Ahlberg, Julian Webber and Bernard Leigh. Although this document is nearly 40 years old and endodontics has advanced hugely in terms of our understanding of the disease and the equipment/materials available, it is worth noting that many of the fundamental principles remain the same.

This guide is not intended to be comprehensive; other guidelines such as the BES/RCS Eng Guidelines for Periradicular Surgery ([britishendodonticsociety.org.uk/professionals/endodontic\\_publications.aspx](http://britishendodonticsociety.org.uk/professionals/endodontic_publications.aspx)) and the IADT Dental Trauma Guide ([iadt-dentaltrauma.org/for-professionals.html](http://iadt-dentaltrauma.org/for-professionals.html)) cover these subjects areas extremely well. This document is a starting point and will evolve with advancements in the discipline; it will be reviewed periodically to ensure it remains contemporary and up to date. The first review is anticipated to be after the publication of the ESE S3-level Clinical Practice Guidelines (Duncan et al 2021).

I would like to thank the BES for supporting this publication, all of the contributors for their tireless work and the council members who gave advice on early drafts of the document, in particular Mark Hunter and Dipti Mehta. Thanks also go to Raj Rattan for his medico-legal contribution and expertise.

We look forward to GEP becoming a reference point for good endodontic standards and contributing to improved patient outcomes and experiences.

## Phillip L Tomson

Senior Clinical Lecturer and Hon. Consultant in Restorative Dentistry

Head of Endodontics

University of Birmingham/Birmingham Community Healthcare NHS Foundation Trust

---

### References

British Endodontic Society (1983). Guidelines for root canal treatment. *International Endodontic Journal*, 16, 192-195

Duncan HF, Nagendrababu V, El-Karim I, Dummer PMH. (2021) Outcome measures to assess the effectiveness of endodontic treatment for pulpitis and apical periodontitis for use in the development of European Society of Endodontology S3-level clinical practice guidelines: A consensus-based development. *International Endodontic Journal*, 54, 2184-2194.

# Chapter 1:

## Endodontic examination and diagnosis

**Making a diagnosis is a process that begins with collecting accurate information from the patient verbally, conducting a clinical examination, carrying out special tests and assimilating the facts to determine the disease or the problem that the patient has.**

### Presenting complaint

Patients who present with urgent endodontic problems may be in acute pain and distressed physically or emotionally due to lack of sleep, anxiety and symptoms related to the pathosis. Equally, patients may be asymptomatic at the time of presentation, for example, in the case of patients who are referred by colleagues. Lack of symptoms should also be noted.

It is important to establish trust and rapport from the outset. Engaging with a distressed patient involves a degree of empathy but with the purpose of extracting essential facts about the presenting issue or symptoms. Questions should be posed in a way that invites openness from the patient to express their complaint rather than closed questions that simply require “yes/no” answers. The dialogue will also give the clinician an indication of the patient’s anxiety levels and attitude towards dental treatment.

To relieve a patient’s anxiety, particularly if it is their first attendance, an initial interview in a non-clinical (‘consultation’) room, or sitting directly in front of them at the same eye-level in the operatory room with an empathetic manner, can help reduce anxiety and encourage an open dialogue.

The initial discussion is only the first stage in developing a diagnosis so it is important that the clinician does not prejudge the condition purely from this.

Symptoms of facial or intra-oral swelling are usually indicative of acute inflammation as a result of infection but may not always be an endodontic issue. Key facts should be noted and recorded in the clinical records. The mnemonic ‘SOCRATES’ is a guide to questioning with the patient:

<b>Site</b>	Where is the pain?
<b>Onset</b>	When did the pain start, and was it sudden or gradual?
<b>Character</b>	What is the pain like? An ache? Stabbing?
<b>Radiation</b>	Does the pain radiate anywhere?
<b>Associations</b>	Are there any other signs or symptoms associated with the pain?
<b>Time course</b>	Does the pain follow any pattern?
<b>Exacerbating/relieving factors</b>	Does anything change the pain?
<b>Severity</b>	How severe is the pain? (use a scale between 1-10)

If the case involves trauma or a history of trauma then it is important to record essential information of the incident for clinical and medico-legal reasons:

- Time, date, and location of incident
- Loss of consciousness or dizziness after the trauma
- Medical history, particularly noting tetanus status, seizures, current medication, bleeding disorders and allergies
- Emergency treatment that was performed, including the patient/parent's actions, after the trauma e.g. tooth was re-implanted, fragments retained, lost, stored
- Type, time and location of any other treatment that was provided prior to attending e.g. at local hospital

Information gathering can also include telephone discussions in addition to face-to-face conversation in the practice. It is important to remember to record such phone calls in the patient's record.

Once the history is complete, it is a good idea to provide the patient with a brief summary of the information to ensure accuracy.

### Extra-oral examination

In a patient who presents with an acute facial swelling and signs of general distress, there is a possibility that the dental infection may have spread systemically. Although these types of cases are rare, when they present it is imperative that the clinician can identify a provisional diagnosis and take appropriate action swiftly. Recording body temperature and noting difficulty in swallowing in a patient who is clearly suffering with malaise or fatigued from acute symptoms will give an indication of systemic involvement or local spreading infection. Difficulty in breathing may indicate a restricted airway due to sublingual spread of infection (of possible endodontic origin). This requires referral to hospital for admission as the health of the patient can rapidly deteriorate.

Recording the site and size of facial asymmetry will indicate the likely location and spread of infection (e.g. developing cellulitis). A digital face map is useful to record any abnormalities (**Figure 1.1**).

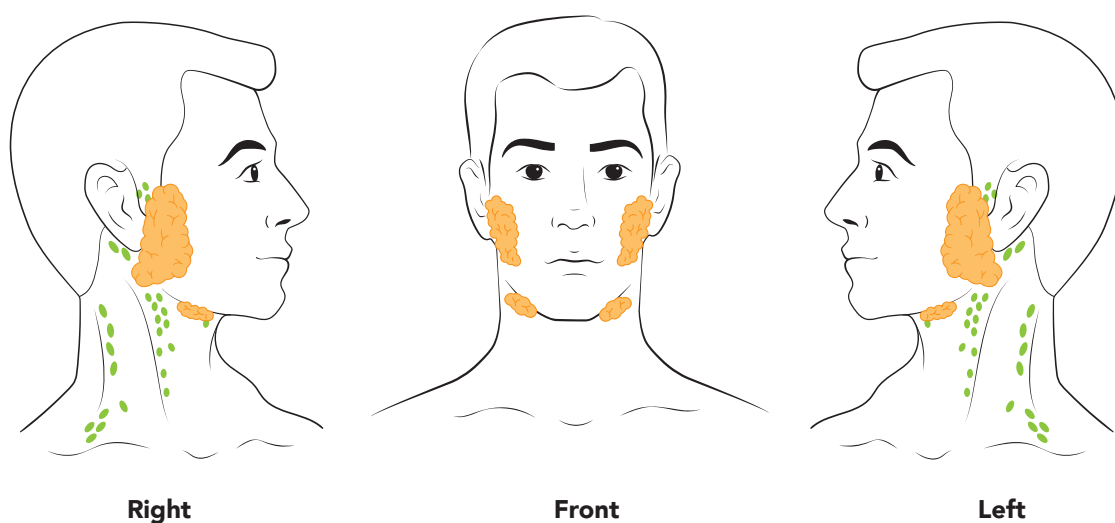


Figure 1.1: Extra-oral map to enable any abnormal clinical findings to be recorded



The temporomandibular joint (TMJ) and lymph nodes should be palpated and any aberrations noted. Apparent pain from the periauricular area may be of referred endodontic origin so TMJ dysfunction should be ruled out in the diagnostic process.

## Intra-oral examination

The intra-oral examination will begin to indicate a possible dental cause of the presenting complaint. General plaque control levels should be noted as this will give an indication of a patient's motivation and level of dental maintenance.

An overall examination of the oral mucosa for aberrations of normal appearance should be performed and photography or recording on a 'mouth map' can be useful as a reference for future comparison. It is the responsibility of any dental professional who examines a patient to be able to identify mucosal abnormalities and arrange for appropriate investigation or referral regardless of the remit of their routine practice. A copy of the referral letter should be retained as part of the patient's clinical records.

**Focusing on the region of the presenting symptoms, the appearance of the soft and hard tissues should be recorded in terms of:**

- Contour
- Texture e.g. firmness, fluctuancy of swellings
- Colour e.g. erythematous, yellow
- Presence of a fistula or suppuration emerging from the soft tissues

Good illumination and magnification during examination are beneficial in order to discern subtle deviations from normal health. A digital intra-oral map is useful to record any abnormalities or signs of pathology (**Figure 1.2**).

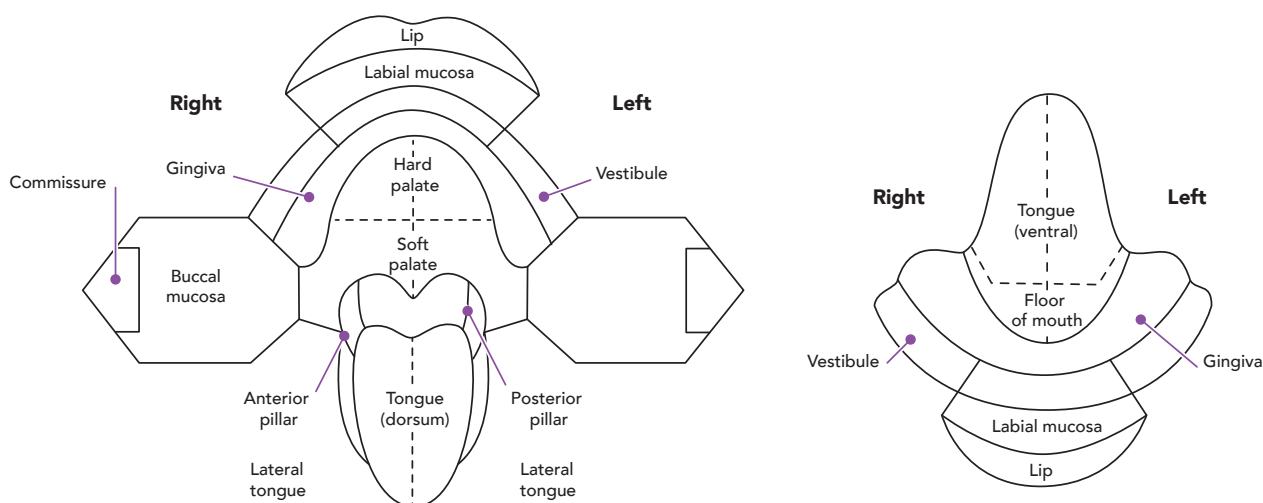
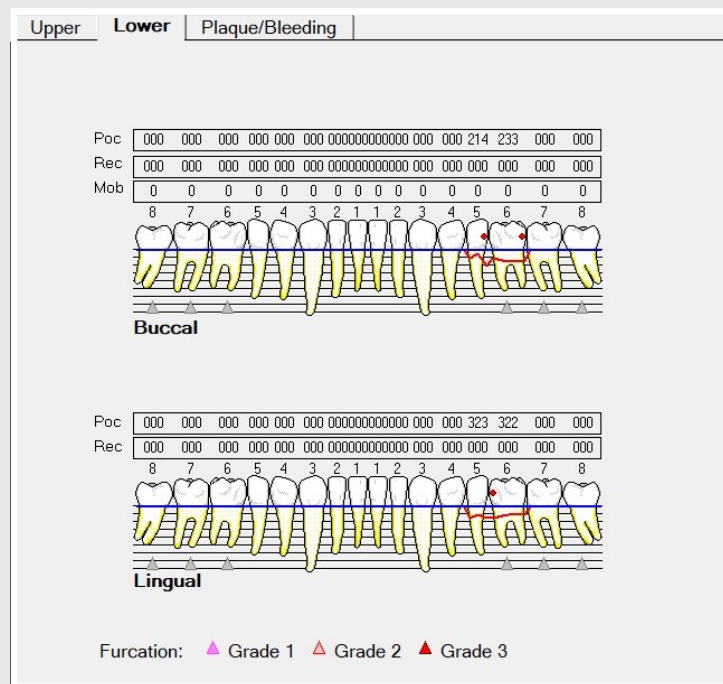


Figure 1.2: Intra-oral map to enable abnormal clinical findings to be recorded

Recording of periodontal attachment levels at six points around a suspect tooth/teeth is essential (**Figure 1.3**). If there are pockets greater than 5.5mm (equivalent of BPE code 4) around a tooth then a full-mouth periodontal assessment should be performed (Dietrich et al 2019). Alternatively, appropriate advice should be forwarded on to the referring colleague to perform further investigation.

Isolated periodontal pockets around a tooth may indicate an endodontic issue: e.g. vertical fracture, root perforation or simply a draining sinus tract (i.e. periodontal pathology 'secondary' to endodontic pathosis).



**Figure 1.3:** Local periodontal chart of the endodontically affected teeth (Reproduced with permission from EXACT Professional, Version 13, 2021. Software of Excellence)

## Hard tissues

A full dental chart should be recorded noting all missing teeth, restorations, any removable prosthesis, carious and non-carious tooth tissue loss. Static and dynamic occlusal relations should be recorded, noting any migration of teeth, as this may identify sites of occlusal trauma that may contribute to the diagnosis.

**For teeth that may be potentially endodontically affected, the following features should be identified and recorded:**

- Volume of remaining coronal natural tooth structure\*
- Condition of restorations
- Fractures and hairline infractions in the tooth structure
- Discolouration
- Mobility, fremitus and percussive tenderness
- Evidence of a fistula or swelling and tenderness on palpation of the alveolar mucosa adjacent to the affected root or tooth to determine any inflammatory abnormalities in the underlying tissue

**\*Coronal tooth structure:**

Endodontic treatments will often be carried out when a significant amount of coronal tooth tissue has been lost due to caries or trauma. The restorability of the tooth should be considered before the decision is taken to carry out endodontic treatment. To obtain predictable results, there should be at least 2mm of circumferential supra-gingival tooth structure and not less than 30% of the original coronal tooth structure remaining (see Chapter 8 - *Restoration of endodontically treated teeth*). An occlusal examination should also be carried out to determine the occlusal scheme for the restoration of the tooth at this early stage.

In patients of mixed dentition, the position of erupted and unerupted teeth and the condition of suspect deciduous or permanent teeth should be noted.

**Dental trauma**

The types of dental trauma are classified as follows:

- Concussion (no physical movement or mobility)
- Subluxation (increased mobility and percussive tenderness)
- Lateral luxation (lateral displacement but the tooth remains in the socket)
- Extrusion (partial displacement in an occlusal direction)
- Intrusion (displacement of the tooth into the socket)
- Avulsion (complete loss of the tooth from the socket)
- Coronal fractures: uncomplicated (enamel, dentine-enamel); or complicated (involving the pulp)
- Root fractures: coronal third; mid-third; apical third

These injuries can occur in isolation or as a combination and should be noted in the clinical records as the treatment plan and prognosis may be affected. Guidelines for the assessment and management of dental trauma are advised by the Internal Association of Dental Trauma (IADT). However it is not the aim of this document to cover these details. Refer to the IADT website for further information.

**■ Key points****History and examination:**

- Give time to your patient and listen to them carefully
- Gather information in a methodical and systematic fashion
- Optimise the clinical examination by using good light, magnification and ensuring nothing obscures vision

## Special tests

Pulp tests are a rudimentary but an essential aid in assessing the broad health of the dental pulp.

Widely available methods include:

- **Thermal:**
  - cold (e.g. compressed refrigerant liquid sprays)
  - heat (e.g. application of hot water after a single tooth rubber dam isolation, electrically-activated heated probe, heated gutta percha stick)
- **Electric pulp test (EPT):** utilises a probe that applies an electrical stimulus to a tooth at variable intensity and can give a digital reading which can be of significance if compared to a contra lateral tooth.
- **Selective anesthetic:** for example, if symptoms are poorly localised between the upper or lower jaw then an inferior dental block will help to determine and assist in localising the source. If symptoms are within a quadrant then local infiltration or intraligamentary anesthesia may help isolate the suspected tooth.

For any of these tests, the patient should be informed of the nature of the investigation. Care should be taken to use language that is non-threatening and that will give the patient full control too. In the first instance when selecting a thermal test, the practitioner should try and replicate the exacerbating factor the patient identifies with most commonly, be that hot or cold. Ethyl chloride ( $-5^{\circ}\text{C}$ ) has been used for many years but non-polluting hydrochlorofluorocarbons (HCFCs) refrigerant spray such as tetrafluoroethane (TFE) at approximately  $-26^{\circ}\text{C}$  is now considered to be more effective. Electric pulp tests are accurate when testing vital teeth but poor when testing non-vital teeth. Cold tests are effective for testing vital and non-vital teeth and should be used as a first line test.

Care must be taken to apply the stimulus to sound, dry tooth structure together with adequate isolation as required, avoiding contact with restorations. Application of the test stimulus onto the supragingival, dry and the thinnest enamel or exposed dentine surface of a tooth's crown is ideal in order to get an optimal response. Testing a tooth that will act as a control, which is distant to the suspected tooth, such as the contralateral tooth will give a baseline reference of response for that particular patient. This should be carried out before the suspect tooth is tested. Multiple aspects of the suspect tooth should be tested that relate to the pulp anatomy [e.g. cervical level of each root of a multi-rooted tooth (**Figure 1.4**)].

Responses from all the tested surfaces should be recorded, including the nature of the response (e.g. sharp, dull pain), duration, referral of pain and a lack of response.

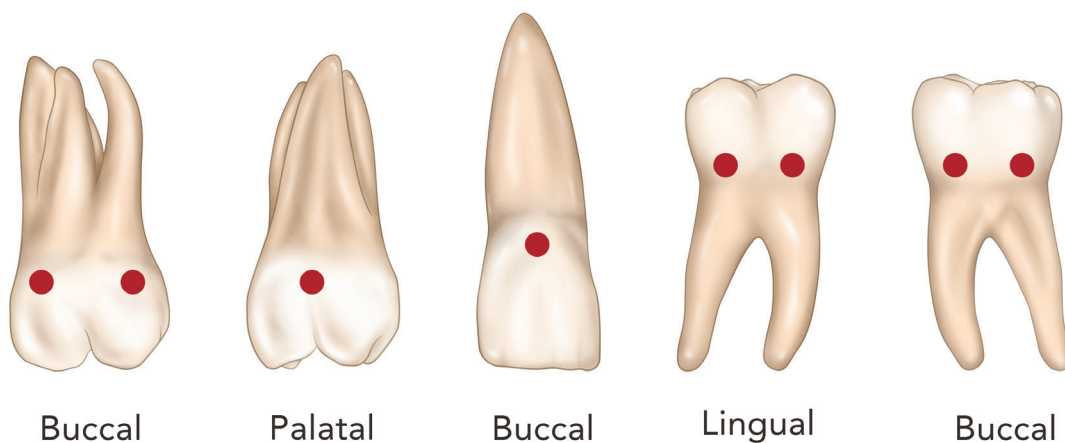


Figure 1.4: Application point of pulp test stimulus (red dot)

**False positive** responses (from a non-vital tooth) can occur in anxious individuals, young patients or in partially vital teeth or when in close contact with the gingival tissues or metallic restorations.

**False negative** responses (in vital teeth) can occur in heavily restored teeth, older patients (due to deposition of secondary dentine), recently traumatised teeth, partially vital teeth and teeth that are undergoing or have had recent orthodontic treatment. Patients under the influence of sedative drugs or alcohol may also have an increased threshold to pulp testing.

Due to the crude nature of pulp tests and the lack of available quality evidence for their precision, (Mejäre et al 2012) results from pulp tests must be always be viewed with a degree of scepticism and put into context with other information gathered about the condition.

**Other special tests include:**

- Examination for cracked cusps with transillumination, magnification and biting devices (e.g. ‘tooth sleuth’). These can be used to identify partial coronal fractures in vital teeth.
- Percussion testing, traditionally preformed with the end of a mouth mirror, reveals the health of the periodontal supporting structure and not the health of a suspect pulp. Note that there are multiple causes for percussive tenderness which include occlusal trauma (due to hyperocclusion or an interference), excessive orthodontic forces, recent trauma, acute gingival/periodontal disease and an apical periodontitis/abscess of endodontic origin.
- A test cavity is an invasive test of last resort. The suspect tooth is accessed without local anaesthesia, preferably in a restoration to start with, to test if there is a response.

## ■ Key points

### Pulp tests:

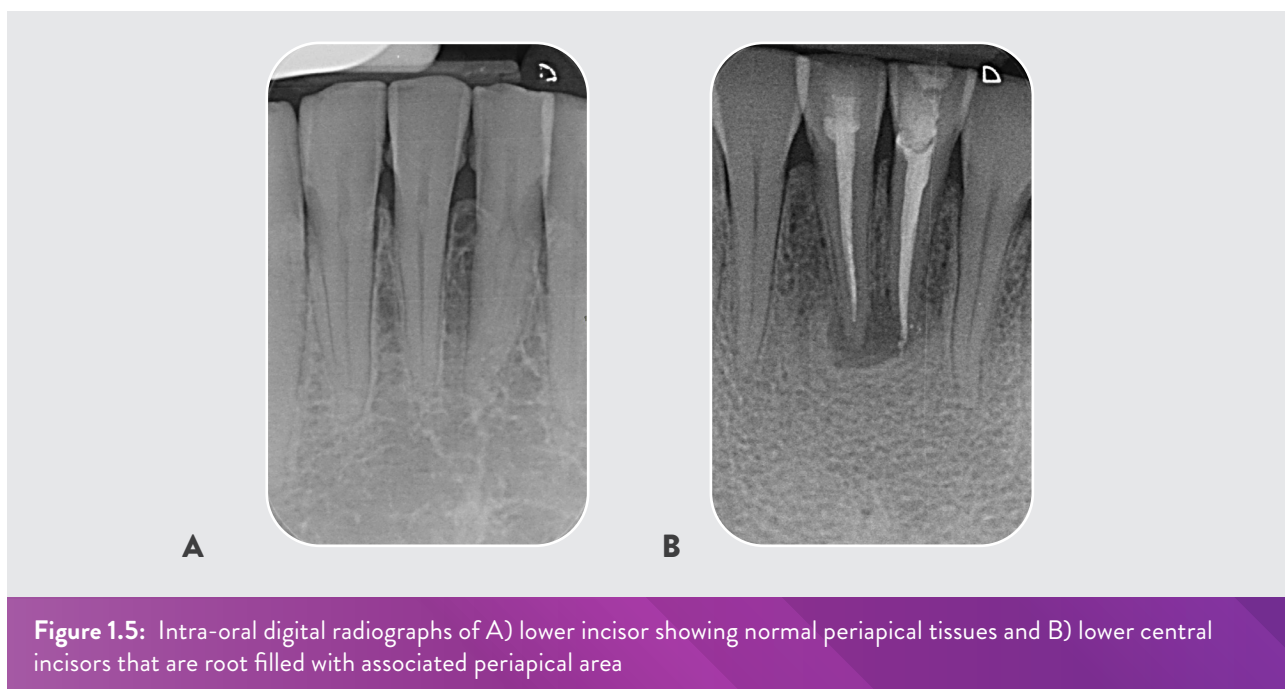
- Suspect teeth should be tested after a control tooth/teeth
- Cold tests are considered the first line test to give an indication of pulp health
- Be wary of false negative pulp tests particularly in older patients, heavily restored teeth and teeth that have experienced recent trauma

## Radiographic imaging

Conventional periapical radiographs should be taken with justification after the clinical examination (Horner and Eaton 2018). Appropriate optimisation is essential to deliver lower doses to patients in line with ALARP principles.

Beam aiming devices are essential for consistent parallel images. The final exposure should reveal at least 3mm of normal tissue beyond the root apex and border of any radiographic lesion. Multiangular periapical views (parallel and 15° to 30° parallax projections) are useful for multi-rooted and re-treatment cases in order to assess the tooth and surrounding tissues in more than one plane.

Digital imaging is now well established and has the potential to lower exposure doses. Currently available radiographic imaging software has the facility to enhance radiographic images to aid the operator in diagnosis, treatment planning and visualisation during endodontic treatment (**Figure 1.5**).



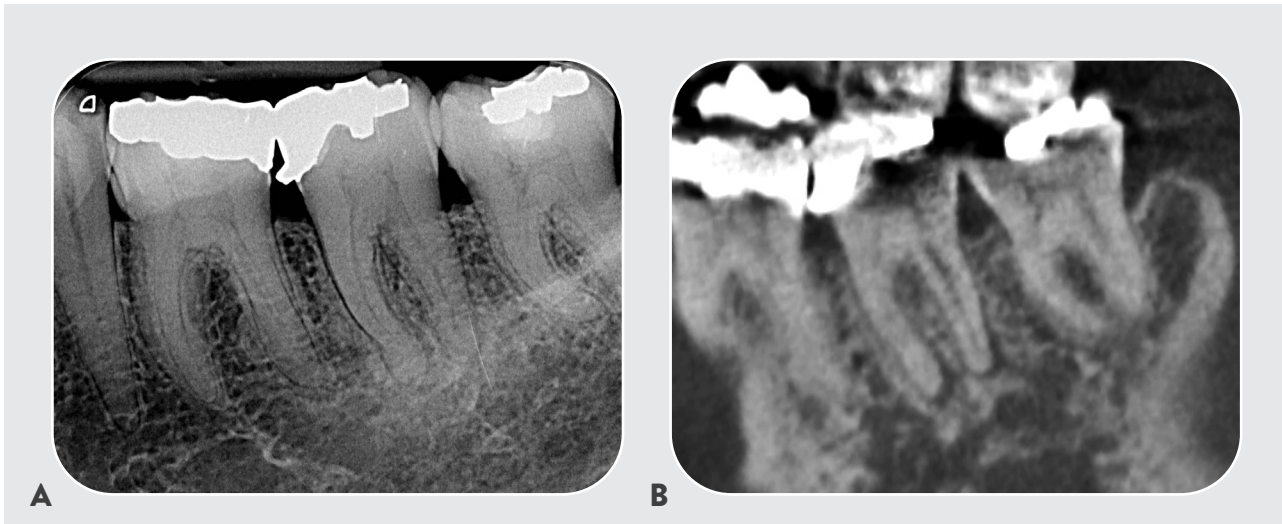
**Figure 1.5:** Intra-oral digital radiographs of A) lower incisor showing normal periapical tissues and B) lower central incisors that are root filled with associated periapical area

Cone beam computed tomography (CBCT) produces a set of images to a certain cylindrical volume (diameter x length) and powerful software will create an accurate three-dimensional reconstruction of them. Indications for CBCT exposure in endodontics are quite specific and should only be considered to aid diagnosis, treatment planning or execution of treatment after conventional radiographs have been taken (Patel et al 2019).

### Indications include:

- Detection of pathosis when the signs and/or symptoms are non-specific and plain film imaging is inconclusive (**Figure 1.6**)
- Analysis of complex root canal systems prior to endodontic management (e.g. dens invaginatus)
- Assessment and/or management of resorption which appears to be treatable
- Presurgical assessment prior to more complex periradicular surgery (e.g. adjacent to anatomically sensitive structures or large lesions)
- Identification of extensively obliterated canals to spatially locate them

It is mandatory that all CBCT scans are reported on and any unusual findings documented and followed up.



**Figure 1.6:** Radiographic imaging of left mandibular molars. A) Periapical image showing no obvious pathology, however B) displays the same teeth in a sagittal view with CBCT imaging showing periapical pathology associated with both roots of the second mandibular molar

## ■ Key points

### Radiographic imaging:

- Any X-ray prescribed should be justified and follow ALARP principles
- A good quality periapical radiograph is required to make an endodontic diagnosis
- 3mm of sound tissue should be seen beyond any pathological finding
- CBCT images should be reported on by a suitably qualified individual

## Diagnosis

After assimilation of the symptoms, clinical examination and results of the special tests, a diagnosis or provisional diagnoses can be made. Presentation of treatment options to the patient and subsequent planning should be made only after a correct diagnosis has been confirmed and recorded. Any endodontic treatment suggested should take into account the overall treatment strategy for the patient.

Current terminology related to diagnosis in endodontics based on the AAE guidelines are in Table 1.1:

Diagnosis	Symptoms/signs	*Radiographic feature
<b>Reversible pulpitis</b>	<ul style="list-style-type: none"> <li>• Short, sharp sensitivity to cold</li> <li>• Localised to the affected tooth</li> <li>• Questionable restoration, coronal fracture</li> </ul>	<ul style="list-style-type: none"> <li>• Normal appearance of apical tissues</li> </ul>
<b>Irreversible pulpitis</b>	<ul style="list-style-type: none"> <li>• Spontaneous pain, lingering, sporadic, poorly localised to a specific tooth</li> <li>• Can radiate away from the source</li> <li>• Pain may refer to adjacent teeth, face, jaw, auricular, temporal regions</li> </ul>	<ul style="list-style-type: none"> <li>• Normal apical tissues but may show early signs of apical involvement if longstanding e.g. widening of the pdl space, loss of lamina dura</li> </ul>
<b>Pulp necrosis</b>	<ul style="list-style-type: none"> <li>• None, or vague history of intermittent symptoms which completely settle</li> </ul>	<ul style="list-style-type: none"> <li>• Normal apical tissues but may show early signs of apical involvement if longstanding e.g. widening of the pdl space, loss of lamina dura</li> </ul>
<b>Transient apical periodontitis</b> (e.g. occlusal trauma, dental trauma)	<ul style="list-style-type: none"> <li>• Percussive tenderness of the affected tooth</li> <li>• Similar to a reversible pulpitis: thermal hypersensitivity of short duration</li> </ul>	<ul style="list-style-type: none"> <li>• Intact lamina dura</li> <li>• Widening of the pdl space around the root in response to excessive occlusal forces or interference</li> </ul>
<b>Symptomatic apical periodontitis</b>	<ul style="list-style-type: none"> <li>• Percussive tenderness</li> <li>• Tenderness upon palpation of periapical soft/hard tissues of the affected tooth</li> <li>• Sporadic pain, odd niggles</li> </ul>	<ul style="list-style-type: none"> <li>• Widening of the pdl space</li> <li>• Loss of lamina dura</li> </ul>

Table continued over page »



Diagnosis	Symptoms/signs	*Radiographic feature
<b>Asymptomatic apical periodontitis</b>	<ul style="list-style-type: none"> <li>No symptoms</li> <li>Sometimes small, firm (bony) swelling over periapex of affected tooth</li> </ul>	<ul style="list-style-type: none"> <li>Rarefaction of apical bone architecture around roots (radiolucency)</li> </ul>
<b>Chronic apical abscess</b>	<ul style="list-style-type: none"> <li>Little or no symptoms</li> <li>Discharging suppurating sinus</li> </ul>	<ul style="list-style-type: none"> <li>Rarefaction of apical bone architecture around roots (radiolucency)</li> </ul>
<b>Acute apical abscess</b>	<ul style="list-style-type: none"> <li>Severe pain and swelling</li> <li>Intra-oral: often fluctuant</li> <li>Extra-oral: more diffuse progressing to cellulitis</li> </ul>	<ul style="list-style-type: none"> <li>Typically little or no obvious radiographic changes (unless the condition is an acute exacerbation of an existing apical periodontitis)</li> </ul>
<b>Condensing osteitis</b>	<ul style="list-style-type: none"> <li>Variable symptomology</li> <li>May be associated with either symptomatic or asymptomatic apical periodontitis</li> </ul>	<ul style="list-style-type: none"> <li>Diffuse radiopaque lesion representing a localised bony reaction to a low-grade inflammatory stimulus, usually seen at apex of tooth</li> </ul>

**Table 1.1:** Summary of diagnostic terminology with associated symptoms, signs and radiographic appearance

## References:

American Association of Endodontists (2009) AAE Consensus Conference Recommended Diagnostic Terminology. *J. Endo.* 35(12).

Dietrich T, Ower P, Tank M, Walter C, Needleman I, Hughes F J, Wadia R, Milward M R, Hodge P J, Chapple ILC. Periodontal diagnosis in the context of the 2017 classification of periodontal diseases and conditions – implementation in clinical practice. *Brit. Dent J.* 2019. 266:12-22.

Horner K, Eaton KA (2018) Selection Criteria for Dental Radiography. 3rd edition. FGDP (UK).

IADT Guidelines for the Evaluation and Management of Traumatic Dental Injuries (2020). [www.iadt-dentaltrauma.org/for-professionals.html](http://www.iadt-dentaltrauma.org/for-professionals.html) [accessed on 20th June 2021].

Mejäre IA, Axelsson S, Davidson T, Frisk F, Hakeberg M, Kvist T, Norlund A, Petersson A, Portenier I, Sandberg H, Tranaeus S, Bergenholtz G. (2012) Diagnosis of the condition of the dental pulp: a systematic review. *Int Endod J.* 45(7):597-613.

Patel S, Brown J, Semper M, Abella F, Mannocci F. (2012) European Society of Endodontology position statement: Use of cone beam computed tomography in Endodontics. *Int Endod J.* 52(12):1675-1678.

Contents

Foreword

Preface

Chapter 1

Chapter 2

Chapter 3

Chapter 4

Chapter 5

Chapter 6

Chapter 7

Chapter 8

Chapter 9

# Chapter 2

## Case difficulty assessment and knowing when to refer

Endodontic treatment is technique sensitive and like any healthcare procedure, it is not risk-free. Procedural errors during root canal instrumentation, disinfection and obturation may result in an unfavourable outcome and the need for retreatment or extraction (Ng et al. 2011). Such procedural errors are influenced by the level of operator knowledge, skill and experience in managing various patient and treatment-related prognostic factors (Ng et al. 2011). Therefore, challenging endodontic cases may be beyond the skill and experience of some operators and it is crucially important for a clinician to understand their own limits. Certain tools exist to aid the determination of case complexity and guide management of care.

### Case difficulty assessment tools

Case difficulty assessment tools that use clinical and radiographic information may assist General Dental Practitioners (GDPs) or other operators with little experience in endodontics to determine treatment complexity and suggest appropriate treatment delivery pathways. Examples of endodontic case difficulty assessment tools include:

- American Association of Endodontists (AAE) case assessment difficulty form (AAE 2006)
- Complexity assessment for Levels of Endodontic Care (LEC) from The Commissioning Standard for Restorative Dentistry (NHS England 2019)
- The British Endodontic Society (BES) case assessment tool – BES EndoApp
- Endodontic complexity assessment tool (E-CAT; Essam 2021)

The comprehensiveness of these tools makes them more appropriate to systematically determine and/or summate the risk levels for endodontic cases. Of these, only the LEC and BES EndoApp help produce recommendations on the treatment pathways that are relevant for the UK dental profession as they consider referral to Dentists with Enhanced Skills in Endodontics (DwESE), Specialist Endodontists (SpEs) or Consultants. DwESE are dentists who have received further training to provide enhanced endodontic services (Al-Haboubi et al. 2014). Therefore, within the limits of their competencies, they can accept referrals from GDPs and refer more complicated cases to SpEs or Consultants (Al-Haboubi et al. 2014).

The use of case difficulty assessment tools, after examination and diagnosis of endodontic problems by inexperienced dentists, should be used to ensure endodontic cases are appropriately handled. This will reduce the chances of any issues, medico-legal consequences and pain/discomfort for the patient. Case difficulty assessment tools can also help GDPs explain the complexity of cases to patients, gain valid consent and improve record keeping. They also have a role in undergraduate and postgraduate dental education, research and triage (Shah and Chong 2018).

Case difficulty assessment tools are not without limitations as they rely on the accuracy of chosen answers and do not assess the level of experience and skill of individual users. Furthermore, the availability of operators, access to NHS services and patient treatment needs vary between and within geographic areas. Therefore, all information must be collated within a wider context.

## The LEC tool

Before starting any endodontic treatment or referral, a stable oral environment should be established with no active caries present and sufficient volume of sound tooth structure above the gingival margin to permit restoration and function of the tooth in question.

The LEC is a simple table that has classified the difficulty of endodontic treatment into three levels which broadly correspond to the operator's skill and experience in endodontics, to help determine the appropriate treatment delivery pathway (**Table 2.1**). The dental practitioner must perform a thorough examination and be capable of diagnosing and determining the level of complexity for endodontic cases in order to responsibly treat or refer based on the criteria listed in Table 2.1.

Complexity levels for endodontic treatment	
<b>Level 1</b> GDPs	<ul style="list-style-type: none"> <li>• Root canal curvature &lt;30° to root axis and deemed negotiable, radiographically, through their length</li> <li>• No root canal obstruction or damaged access, e.g. perforation</li> <li>• Previously treated teeth with short, poorly condensed root fillings and evidence of probable canal patency beyond existing root filling</li> <li>• Routine dismantling of plastic restorations, crowns and bridges to assess restorability</li> <li>• Pulp extirpation as an emergency treatment</li> <li>• Incision and drainage as an emergency treatment</li> <li>• Straightforward retreatment</li> <li>• Any endodontic treatment not covered in Level 2 or 3 procedural complexity</li> </ul>
<b>Level 2</b> DwESEs SpEs	<ul style="list-style-type: none"> <li>• Root canal curvature 30-45°</li> <li>• Location and negotiation of canals deemed NOT negotiable in the coronal third but patent thereafter, based on radiographic and clinical evidence</li> <li>• Location and negotiation where the referring dentist has experienced problems with canal location, instrumentation or obturation</li> <li>• Local analgesia difficulties that cannot be resolved by routine measures</li> <li>• Teeth &gt;25 mm in length</li> <li>• Incomplete root development</li> <li>• Limited mouth opening (25-35mm inter-incisal)</li> <li>• Short but well condensed root fillings with evidence of likely patency beyond existing root filling and an absence of complicating factors involving the previous treatment</li> <li>• Removal of fractured posts, less than 8mm in length</li> </ul>

Table continued over page »

Complexity levels for endodontic treatment	
<b>Level 3</b> SpEs Consultants	<ul style="list-style-type: none"> <li>• Root canal curvature &gt;45°</li> <li>• Recurved (S-shaped) root canals</li> <li>• Canals deemed NOT negotiable through their entire length based on radiographic and clinical evidence</li> <li>• Presence of developmental tooth anomalies, e.g. bifid apex, complex branching of root canal(s), dens-in-dente, gemination and C-shaped canals</li> <li>• Assessment and planning for the long-term management of severely traumatised teeth with pulpal involvement and/or multiple teeth</li> <li>• The management of teeth with iatrogenic damage or pathological resorption</li> <li>• Severely limited mouth opening (&lt;25 mm inter-incisal)</li> <li>• Complicated retreatments (e.g. well-fitting posts longer than 8mm; posts thought to be associated with a perforation; carrier-based obturations; silver points; fractured instruments; well condensed root fillings to length; overfilled roots with apical lesions)</li> <li>• Major iatrogenic errors e.g. large ledges, blocked canals, perforations where these can be rectified</li> <li>• Periradicular surgery</li> </ul>

**Table 2.1:** The complexity levels for endodontic treatment detailing their respective operators and inclusion criteria for the management of patients requiring endodontic care (adapted from NHS England 2019)

## The BES EndoApp

The BES EndoApp is a web-based tool, adapted from EndoApp (Shah and Chong 2018), incorporating a concise case difficulty assessment questionnaire into a user-friendly, structured, and automated interface with graphical representations where appropriate (**Figure 2.1**). It was designed to help dentists with little or no experience in endodontics to manage cases of varying complexities requiring non-surgical root canal treatment. The BES EndoApp generates a score and corresponding recommendation on the treatment delivery pathway (**Table 2.2**) by summing the weightings of various treatment difficulty factors that appear in the questionnaire. An email summarising the chosen responses and recommendation is sent if a user email address was provided. The BES EndoApp is accessible on the BES website under case assessment tool or by scanning the QR code (**Figure 2.2**).

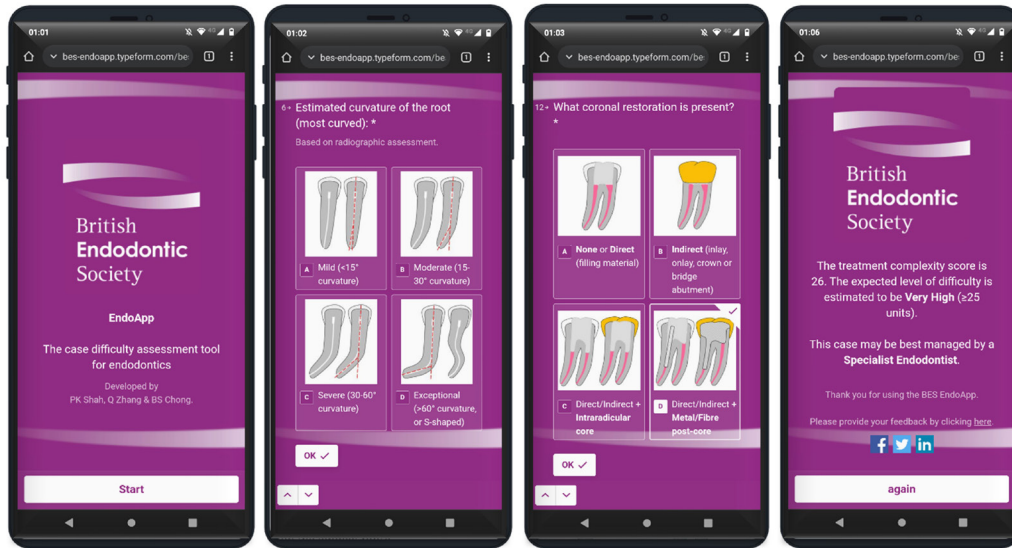


Figure 2.1: Screenshots of The BES EndoApp showing the various assessment criteria and graphical representations

Final score range (units)	Level of difficulty	Recommended treatment route
1 – 12	Low	GDP
13 – 16	Average	DwESE or GDP
17 – 24	High	DwESE or SpE or Consultant
≥ 25	Very high	SpE or Consultant
0	Diagnostic challenge	DwESE or SpE or Consultant

Table 2.2: The recommendations on the treatment delivery pathway generated by The BES EndoApp based on the respective levels of difficulty and final score ranges



Figure 2.2: QR code to access The BES EndoApp

## When to treat or refer?

Treatment should only be undertaken if the technical demands and knowledge are within the competences and abilities of the operator (General Dental Council 2013), otherwise a referral to a DwESE, SpE or Consultant is required. Referral letters should contain:

- Patient details (salutation, name, address, date of birth and contact details)
- Patient's main complaint and history of the presenting problem
- Relevant medical, dental and social histories
- Examination findings including results of special tests and a restorability assessment (if possible)
- Diagnostically acceptable periapical radiograph(s) of the tooth requiring treatment
- A provisional or definitive diagnosis
- Justification for the referral based on the case difficulty assessment
- Details of any failed attempts at treatment e.g. type/size of separated instrument, location of perforation etc

When a case is properly assessed and suitably managed by a clinician with the appropriate level of skill, a favourable outcome is likely. This will translate into savings in terms of financial outlay, pain and suffering for patients. Therefore, case difficulty assessment tools are particularly relevant for operators with limited experience in endodontics to help guide decision making on the patient's treatment delivery pathway.

### ■ Key points

- **Case difficulty assessment tools may assist in determining treatment complexity and suggest appropriate treatment delivery pathways**
- **Treatment should only be undertaken if the technical demands and knowledge are within the competencies and abilities of the operator**
- **When a case is properly assessed and suitably managed by a clinician with the appropriate level of skill, a favourable outcome is likely**



## References

Al-Haboubi M, Eliyas S, Briggs PF, Jones E, Rayan RR, Gallagher JE (2014) Dentists with extended skills: the challenge of innovation. *British Dental Journal* 217, E6.

American Association of Endodontists (2006) AAE Endodontic Case Difficulty Assessment Form and Guidelines [WWW document]. URL [www.aae.org/specialty/wp-content/uploads/sites/2/2019/02/19AAE\\_CaseDifficultyAssessmentForm.pdf](http://www.aae.org/specialty/wp-content/uploads/sites/2/2019/02/19AAE_CaseDifficultyAssessmentForm.pdf) [accessed on 22 February 2022].

Essam O, Boyle EL, Whitworth JM, Jarad FD (2011) The Endodontic Complexity Assessment Tool (E-CAT): A digital form for assessing root canal treatment case difficulty. *International Endodontic Journal* 54, 1189-1199.

General Dental Council (2013) Standards for the dental team. General Dental Council London.

Ng Y-L, Mann V, Gulabivala K (2011) A prospective study of the factors affecting outcomes of nonsurgical root canal treatment: part 1: periapical health. *International Endodontic Journal* 44, 583-609.

NHS England (2019) Commissioning Standard for Restorative Dentistry. [WWW document]. URL [www.england.nhs.uk/publication/commissioning-standard-for-restorative-dentistry/](http://www.england.nhs.uk/publication/commissioning-standard-for-restorative-dentistry/) [accessed on 22 February 2022].

Shah PK, Chong BS (2018) A web-based endodontic case difficulty assessment tool. *Clinical Oral Investigations* 22, 2381-2388.

Contents

Foreword

Preface

Chapter 1

Chapter 2

Chapter 3

Chapter 4

Chapter 5

Chapter 6

Chapter 7

Chapter 8

Chapter 9

# Chapter 3

## Good endodontic record keeping

**Record keeping in endodontics is no different to the requirements of a dental professional providing dental care for patients in any other sphere of dental practice.**

**Generally, dental records include any relevant documentation related to a patient, such as:**

- Personal data
- Medical history
- Dental history
- Presenting complaint(s)
- Clinical notes (including diagnosis, treatment options, treatment performed, postoperative advice, reviews, adverse events)
- Photographic, radiographic and digital images/scans
- Digital, verbal and written communications with the patient
- Digital, verbal and written communications with relevant third parties (e.g. referral letters, reports from secondary/tertiary care providers, dental laboratories)
- Financial transactions between providers and patient and with third parties (e.g. insurance companies) relating to the dental care of a patient
- Documents and notes of discussions relating to consent

Providers of endodontic care should ensure that they ‘make and keep accurate and complete patient records, including a medical history, at the time you treat them’ (GDC 2013).

Records must be legible, concise and comprehensible by a third party or members of the dental team. Hand-written and digital records should be dated, timed and signed by the author(s) who should be easily identifiable. Amendments to records should be clear, dated and signed by the editor.

Information about patients should be confidential. Every effort should be made to keep it secure and prevent unauthorised access (GDC 2013). All records should be correctly and securely stored (Data Protection Act 2018). Digital clinical and dental records should be regularly backed up and have restricted access by appropriate members of practice staff.

All dental records should not be kept longer than is necessary (Data Protection Act 2018) but should be retained securely for a minimum of 11 years from the date of the patient’s last attendance or to the point a patient would reach 25 years of age when seen as a child (whichever is longer) (FGDP 2016).

If records are transferred electronically, the provider must ensure, as far as is practically possible, that only the recipient will have access to the data, the data is password-protected and the recipient is advised of this. The transfer of data should be subject to end-to-end encryption.

Patients have full entitlement to access their records. All members of the dental team have a professional duty to maintain confidentiality with regards patient information (GDC 2013). Confidentiality may be broken in exceptional situations such as safeguarding issues or in the investigation of a criminal case related to the patient.

## Pre-examination records

It is essential that a patient's personal details are obtained at the first point of contact or attendance, including their contact details and date of birth.

### Medical history

Obtaining a record of relevant medical history is imperative prior to the clinical examination as it provides the background on the patient's general health. This will indicate whether a patient is medically suited to treatment in a practice setting.

The medical history must be dated and signed by both patient and clinician, checked at subsequent visits and amended as necessary.

### Social and dental history

Knowledge of a patient's social, dental, familial and professional background can give an insight to their suitability for receiving endodontic or advanced restorative treatment (e.g. ability to attend for multiple visits, motivation towards dental care, financial motivation towards accepting the treatment). Delivery of endodontic care may have to be tailored based on an individual's needs and circumstances.

The dental history of a patient may also be relevant to presenting symptomology (e.g. recent dental treatment in the vicinity of the symptoms). It also gives the clinician an idea of a patient's general attitude towards dental care (e.g. dental phobia, attendance history, motivation).

## Examination

Following the initial discussion with the patient and gathering the history of their presenting complaint, a record of the clinical examination can be made.

The essential components of a good clinical examination are covered in detail in Chapter 1 and include:

- Extra-oral assessment
- Intra-oral assessment in a logical order such as:
  - Overall general state of the oral cavity, tooth charting, plaque control, basic periodontal examination (BPE)
  - General soft tissues (aberrant colouration, textures)
  - Localised soft tissue examination of the symptomatic area
  - Localised hard tissue examination of the symptomatic area
  - Six-point periodontal pocket chart of suspect tooth/teeth
  - Condition of coronal tooth structure and restorations of suspect tooth/teeth
- Endodontic examination of the suspect tooth/teeth: percussion, mobility, palpation of adjacent alveolus
- Special tests:
  - Pulp testing – include results of control teeth
  - Radiographic imaging - long cone periapical radiography and CBCT imaging as necessary  
Ensure justification and a report for any imaging is written clearly in the notes

## Diagnosis and treatment planning

Clinical records should include:

- Provisional diagnoses or definitive diagnosis
- Coherent and rational treatment options that have been discussed with the patient
- Prognosis of the affected dentition and various treatment options
- Outline of the overall treatment strategy

Specific features to note related to examination and diagnosis are covered in more detail in Chapter 1: Endodontic examination.

## Treatment records

Record keeping throughout the delivery of endodontic care is paramount from both clinical and medico-legal perspectives.

For endodontic treatment specifically, the following key components should be recorded in a patient's clinical notes:

- Nature of appropriate, valid consent - confirmation that the patient understands the treatment that has been advised and will be delivered
- Advice on risks and possible complications relevant to that particular case. Such information can be incorporated in a patient information leaflet and may include:
  - Post-operative discomfort
  - Fracture of the tooth beyond repair during treatment
  - Damage to the tooth or root during root canal treatment
  - Blocked root canals that cannot be further treated
  - Failure of root canal treatment leading to persistent infection
  - Dental instrument fracture inside the root canal system
  - Leakage of bleach into the mouth or into the tissues outside the root could result in a bad taste or in the rare / worse extent bad swelling, bruising. In very rare cases such leakage may result in reversible or irreversible nerve damage.
- Local anaesthesia: agent, dose and technique
- Rubber dam isolation
- Magnification used including type (e.g. microscope or loupes)
- Disinfection agents and concentration used (e.g. 2% sodium hypochlorite solution, 17% EDTA, and similar)
- Type of irrigation syringe (e.g. Luer-lock with safe ended needle)
- Canal anatomy: canal labels, working lengths, reference points of measurement, final apical preparation size and taper
- Details of preparation protocol and instrumentation sequence
- Materials used: intracanal dressing, obturation material and sealer, temporary restoration and similar
- Obturation protocol (e.g. warm vertical, cold lateral condensation, thermomechanical compaction, single point or similar)
- Nature of any complications that occur during the procedure and subsequent advice given to the patient
- Radicular preparation related to core restoration (e.g. length and post design)
- Permanent core restoration, if applicable

- Indirect restoration, if applicable
- Advice given to the patient on the definitive restoration for the tooth after completion of endodontic treatment
- Postoperative treatment advice
- Advice on review appointments
- Correspondence and advice sent to any referring colleagues
- Notes of review and follow-up assessments

To facilitate notetaking for the operator and clinical assistant, current digital dental patient management systems allow the development of customisable screens to record essential data related to the treatment, examples of which are shown in **Figures 3.1a and 3.1b**.

RCT Screen

Local Analgesic 2% Lignocaine 1:80,000 Adren ▾ Rubber Dam  Yes  No

Canal	W.L.	M.A.F.	Ref Point	PATENT	Taper
<input type="text"/>	0.0	25	<input type="text"/>	<input type="checkbox"/>	8.0
<input type="text"/>	0.0	25	<input type="text"/>	<input type="checkbox"/>	8.0
<input type="text"/>	0.0	25	<input type="text"/>	<input type="checkbox"/>	8.0
<input type="text"/>	0.0	25	<input type="text"/>	<input type="checkbox"/>	8.0
<input type="text"/>	0.0	0	<input type="text"/>	<input type="checkbox"/>	0.0

Irrigation 5% NaOCl, EDTA ge ▾ Dressing None ▾

Obturation Microseal + Multiphase GP ▾

Sealer MTA/Bioceramic ▾ Temp Dress SDR, Sp/IRM ▾

Core None ▾ Preparation NiTi / Hand / Ultrasonic ▾

OK Cancel

Figure 3.1a: Customisable endodontic record screen (Reproduced with permission from EXACT Professional, Version 13, 2021. Software of Excellence)

RCT Screen

Local Analgesic 4% Articaine 1:200,000 Adren ▾ Rubber Dam  Yes  No

Canal	W.L.	M.A.F.	Ref Point	PATENT	Taper
<input type="text"/>	0.0	25	<input type="text"/>	<input type="checkbox"/>	8.0
<input type="text"/>	0.0	25	<input type="text"/>	<input type="checkbox"/>	8.0
<input type="text"/>	0.0	25	<input type="text"/>	<input type="checkbox"/>	8.0
<input type="text"/>	0.0	25	<input type="text"/>	<input type="checkbox"/>	8.0
<input type="text"/>	0.0	0	<input type="text"/>	<input type="checkbox"/>	0.0

Irrigation 5% NaOCl, EDTA ge ▾ Dressing None ▾

Obturation 3% NaOCl/EDTA Soln GP ▾

Sealer 2%NaOCl/EDTA Soln Temp Dress SDR, Sp/IRM ▾

Core 2% NaOCl /0.2% CHX Preparation NiTi / Hand / Ultrasonic ▾

5% NaOCl, EDTA gel/s  
CHX  
2% NaOCl, EDTA gel/s

Cancel

Figure 3.1b: Custom endodontic record screen with dropdown information boxes with a selection of options/materials to choose (Reproduced with permission from EXACT Professional, Version 13, 2021. Software of Excellence)

## ■ Key points

- Clinical records must be contemporaneous, accurate and comprehensible to any dental professional or third party who has authorised access to them
- Storage of patient information should be secure and only accessible to authorised professionals in line with data protection law
- Clinical notes must be of a sufficient standard to withstand medico-legal scrutiny
- A written diagnosis, treatment options discussed with the patient and treatment plan must ALWAYS be included in the patient records

## Imaging

Occasionally, bitewing radiographs are useful to accurately assess the extent of cavitation and periodontal bone levels local to a tooth or small region. However, periapical radiographs are essential for the delivery of endodontic care and may be supplemented with CBCT radiography. Radiographs should only be taken with proper justification and quality. Clinical records should include the technique of radiographic exposure and quality assessment of images produced.

**The minimum standards and images required for treatment are as follows:**

- Preoperative, and sometimes mid-operative, views (e.g. to ensure correct length prior to obturation) if apex locator readings are erratic or inconsistent with the estimated working length
- Post-obturation
- Review
- Supplemental views can be taken, for example, in the event of intra-operative complications (e.g. perforation, negotiating calcified canals), working length determination, staged obturation or to check post-space preparation

The quality standards required for periapical radiography are in **Table 3.1**.

## ■ Key points

**Periapical radiographs should allow sufficient clarity:**

- to determine restorability of the tooth
- to assess pulp chamber space, canal morphology and curvature
- to determine hard tissue pathology such as resorption
- to assess extent of periradicular pathology



**A: Evidence of optimal image geometry**

- There should be no evidence of bending of the teeth and periapical region of interest on the image
- There should be no foreshortening or elongation of the teeth
- Ideally there should be no horizontal overlap. If overlap is present, it must not obscure pulp/root canals

**B: Correct anatomical coverage**

- The film should demonstrate all of the tooth/teeth of interest (i.e. crown and root(s))
- There should be 2-3mm of periapical bone visible to enable an assessment of apical anatomy

**C: Good density and contrast**

- There should be good density and adequate contrast between the enamel and dentine

**D: Adequate number of films**

- In endodontic treatment it may be necessary to separate superimposed root canals using two radiographs at different horizontal angles. Obtain one 'normal' film and one with a 20° oblique horizontal beam angle for all molars and maxillary first premolars
- Assessment of some horizontally impacted mandibular third molars may require two films to image the apex. Obtain one 'normal' film and one with a more posterior 20° oblique horizontal beam angle

**E: Adequate processing and darkroom techniques**

- No pressure marks on film, no emulsion scratches
- No roller marks (automatic processing only)
- No evidence of film fog
- No chemical streaks/splashes/contamination
- No evidence of inadequate fixation/washing

**Table 3.1:** Quality standards for periapical radiographs [adapted from European Guidelines on Radiation protection in Dental Radiology 2004. European Commission]

## References:

Data Protection Act 2018. <https://www.legislation.gov.uk/ukpga/2018/12/contents/enacted> [Accessed 22nd Sept 2021].

European Commission(2004). Radiation Protection 136: European Guidelines on Radiation Protection in Dental Radiology. Luxembourg: Publications Office of the European Union.

<https://ec.europa.eu/energy/sites/ener/files/documents/136.pdf> [Accessed 30th June 2021].

General Dental Council (2013) Standards for Dental Professionals. <https://www.gdc-uk.org/professionals/standards/gdc-guidance> [ Accessed 12th May 2021].

Freedom of Information Act 2000. <https://www.legislation.gov.uk/ukpga/2000/36/contents> [Accessed 22nd Sept 2021].

Hadden AM (2016) Clinical Examination and Record-keeping. 3rd edition. FGDP (UK).

Montgomery (Appellant) V Lanarkshire Health Board (Respondent) and General Medical Council (Intervener) [2015] Montgomery (Appellant) v Lanarkshire Health Board (Respondent) (supremecourt.uk) [Accessed 30th June 2021].

Patel S, Brown J, Semper M, Abella F, Mannocci F (2019) European Society of Endodontology position statement: Use of cone beam computed tomography in Endodontics. Int Endod J. 52(12):1675-1678.

European Commission (2004). Radiation Protection 136: European Guidelines on Radiation Protection in Dental Radiology. Luxembourg: Publications Office of the European Union. <https://ec.europa.eu/energy/sites/ener/files/documents/136.pdf> [Accessed 30th June 2021].

Contents

Foreword

Preface

Chapter 1

Chapter 2

Chapter 3

Chapter 4

Chapter 5

Chapter 6

Chapter 7

Chapter 8

Chapter 9

# Chapter 4:

## Management of endodontic emergencies

**An endodontic emergency can be defined as pain associated with inflammation of the pulp and/or periradicular tissues or pain caused by infection of the root canal system and/or the periradicular tissues (Abbott 2021).**

The management of endodontic emergencies in dental practice is often a stressful event for all parties. The unexpected arrival of a distressed patient into a busy practice setting, often with appointment time constraints to contend with, can introduce further complexity into an already full clinical day.

The prevalence of dental emergencies is difficult to assess and plan for. A 2015 study in the USA suggested that one in six patients attending general dental practice had experienced orofacial pain within the previous year. Just over 50% of those were dentoalveolar in nature (Horst et al 2015).

Even though emergencies can be challenging to manage, the importance and value to patients of prompt and effective management of dental pain cannot be underestimated. Practitioners should develop a systematic approach to managing endodontic emergencies based on a sound evidence base with the primary purpose to provide pain relief until definitive treatment can be provided.

### Basic principles of emergency endodontic management

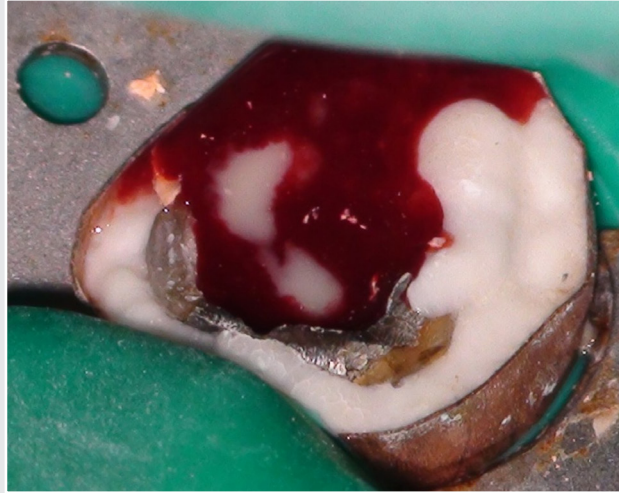
The 3 Ds of managing dental pain (Keiser and Byrne 2011): **D**iagnosis, **D**efinitive dental treatment and **D**rugs; is the recommended approach. For optimal outcomes the process must follow that order. Attempting to treat any disease without first obtaining an accurate diagnosis is likely to result in failure. This is particularly the case when managing endodontic emergencies where the history and symptoms may be variable, clinical examination unremarkable and diagnostic tests confusing. The subject of diagnosis is discussed in more detail in Chapter 1 but it is worth reiterating that an accurate diagnosis is the first step in successful management.

Definitive dental treatment should always be the next stage in the management of endodontic emergencies. As stated above, emergencies are often 'squeezed in' to an already fully booked schedule. This, coupled with the time taken to arrive at an accurate diagnosis, often limits the time available to undertake definitive treatment. However, failure to do so will delay the recovery of the patient. A reliance on the use of drugs alone for expediency is tempting but rarely in the best interests of the patient. Options for definitive treatment of endodontic emergencies are of course driven by the diagnosis, condition of the symptomatic tooth and wishes of the patient. These are discussed in **Table 4.1** as they relate to each individual diagnosis.

Diagnosis	Definitive dental treatment	Drugs
<b>Reversible pulpitis</b>	Placement of restoration with or without vital pulp therapy (see <b>Chapter 5</b> )	NSAIDs
<b>Symptomatic irreversible pulpitis</b>	Pulp chamber access ( <b>Figure 4.1</b> ) and coronal pulpotomy followed by corticosteroid pulpitis (Ledermix/Odontopaste) dressing. If time permits, pulpectomy and full chemo-mechanical preparation of the root canal, dressing with $\text{Ca(OH)}_2$	NSAIDs Consider pre- and post-op Dexamethasone
<b>Symptomatic apical periodontitis</b>	Pulp chamber access and, if time permits, complete chemo-mechanical preparation of the root canal, dressing with $\text{Ca(OH)}_2$ . If time limited, open pulp chamber, disinfect and remove necrotic tissue. Then dress with $\text{Ca(OH)}_2$  Consider occlusal reduction of the symptomatic tooth	NSAIDs Consider pre- and post-op Dexamethasone
<b>Acute apical abscess (no systemic involvement)</b>	Incision and drainage  Pulp chamber access and drainage via root canal with complete chemo-mechanical preparation of the root canal  Consider occlusal reduction of the symptomatic tooth	NSAIDs
<b>Acute apical abscess (systemic involvement)</b>	Incision and drainage  Pulp chamber access and drainage via root canal with complete chemo-mechanical preparation of the root canal  Consider sepsis pathway, monitor symptoms and consider hospital referral if condition is worsening and the airway or eye is threatened	NSAIDs Consider appropriate antibiotic prescription if there are signs of spreading infection

**Table 4.1:** Summary of endodontic emergencies with outline of management

Drugs should only be used as an adjunct to definitive treatment. Endodontic emergencies will only generally require either analgesics or antibiotics - and the latter only in very limited circumstances. Even though definitive treatment is the quickest way to obtain relief for the patient it is common for the symptoms to persist for some time after the treatment and the adjunctive use of an appropriate analgesic regime will help to manage such symptoms.



**Figure 4.1:** Profusely bleeding pulp with pus exuding from pulp chamber after initially accessing a patient's mandibular first molar with irreversible pulpitis

## Management of common endodontic conditions

Management of endodontic emergencies is no different from the provision of any other dental care. Once a diagnosis is established, treatment options and associated risks and benefits should be discussed fully with the patient to ensure that valid consent is gained before any intervention.

Good local anaesthesia for operative procedures is essential for successful emergency treatment and can present a significant challenge in cases where there is localised inflammation or infection (Hargreaves and Keiser 2002). The suggestions below will help to achieve the required depth of anaesthesia.

- Buccal and palatal infiltrations for upper teeth and lower anterior teeth
- Lidocaine 2% with Epinephrine 1:80000 or Articaine 4% with Epinephrine 1:100000, unless medical history contra-indicates
- Lower posterior teeth are associated with a higher failure rate of local anaesthesia in pulpitic cases. Consider the use of supplemental techniques such as a buccal infiltration with Articaine 4% following an Inferior Alveolar Nerve (IAN) block with Lidocaine 2%
- Supplementing standard techniques with intraligamentary or intraosseous injections can be very useful adjunctive techniques for anaesthetising pulpitic teeth

Once optimal local anaesthesia has been achieved then isolation of the tooth is necessary. It may be tempting, to save time, not to use a dental dam. This is not advisable; it leaves the operator open to medico-legal challenge should there be a complication and fails to recognise the benefits that dental dam brings in terms of patient comfort and operator efficiency.

## British Endodontic Society

Operatively, the first steps in treating almost all endodontic emergencies are common to all diagnoses and involve the removal of any caries, cracks and restorative materials from the tooth to help confirm the diagnosis and restorability of the tooth.

The next steps in managing the most commonly encountered endodontic emergencies are listed in **Table 4.1**.

### Use of drugs in endodontic emergency management

As the third arm of the 3D strategy, the use of analgesics and antibiotics is intended as an adjunct to definitive dental treatment - as opposed to a solution in itself.

NSAIDs and paracetamol are the most commonly used analgesic drugs for the management of endodontic pain. Opioid analgesics are not routinely recommended due to their efficacy for odontogenic pain. As a reference document the 'SDCEP Drug Prescribing for Dentistry, Dental Clinical Guidance' (3rd Edition) offers excellent guidance on prescribing analgesics.

The evidence base for the use of antibiotics in endodontic emergency treatment is clear that antibiotics have no efficacy in the treatment of pulpitis or where infection is limited to the peri-radicular tissues (SDCEP). Inappropriate antibiotic prescribing has the potential to cause antimicrobial resistance which is an increasing global problem. The role that a dentist takes in "antibiotic guardianship" cannot be overstated. If there is systemic involvement or the infection has spread, then the use of antibiotics should be reconsidered as per SDCEP guidance.

#### ■ Key points

- Accurate diagnosis is essential for effective management of endodontic emergencies
- Definitive dental treatment should be provided at the emergency appointment wherever possible
- Drugs are very useful in managing dental pain but only as an adjunct to definitive dental treatment
- Antibiotics should not be prescribed for irreversible pulpitis
- When managing an acute endodontic problem, antibiotics should only be prescribed if there are signs of spreading infection (e.g. facial or neck swelling), systemic infection or for an immunocompromised patient

## References:

Abbott P V (2022) Present status and future directions: Managing endodontic emergencies. *International Endodontic Journal* 55 Suppl 3:778-803.

Horst OV, Cunha-Cruz J, Zhou L, Manning W, Mancl L, DeRouen TA (2015) Prevalence of pain in the orofacial regions in patients visiting general dentists in the Northwest Practice-based Research Collaborative in Evidence-based DENTistry research network. *Journal of the American Dental Association* 146,721-728.

Keiser K and Byrne BE (2011) Endodontic pharmacology. Hargreaves KM and Cohen S (Eds.) *Pathways of the Pulp*, 10th edition. St Louis, Missouri, USA: Mosby Elsevier, 671- 690.

Hargreaves KM and Keiser K (2002), Local anesthetic failure in endodontics. *Endodontic Topics*, 1, 26-39.

SDCEP Drug Prescribing For Dentistry Dental Clinical Guidance Third Edition SDCEP-Drug-Prescribing-for-Dentistry-3rd-edition.pdf [Accessed on 28th February 2022].



Contents

Foreword

Preface

Chapter 1

Chapter 2

Chapter 3

Chapter 4

Chapter 5

Chapter 6

Chapter 7

Chapter 8

Chapter 9

# Chapter 5:

## Vital pulp therapy

With a deepening understanding of the importance of conserving dental tissues to avoid the inevitability of the so called ‘restorative cycle’ once the integrity of a tooth is broken, minimally invasive treatment approaches are becoming more established. The importance of preserving a vital pulp is fundamental to such strategies.

Successful maintenance of pulp vitality following injury or threat of injury has numerous benefits:

- The tooth’s defence system is maintained
- The full proprioceptive function of the tooth is maintained
- It enables continual development of the tooth and dento-alveolar complex when the tooth is still forming
- Endodontic treatment of the necrotic pulp is technically demanding and not always successful
- Mechanically weakened endodontically treated teeth are more prone to fracture

### Pulpal diagnosis

The dentine-pulp complex (**Figure 5.1**) is a unique mineralised connective tissue that is composed of two integrated constituents: the pulp - an underlying gelatinous soft connective tissue which has a rich vasculature and is well innervated, and dentine - an outer casing of mineralised tissue.

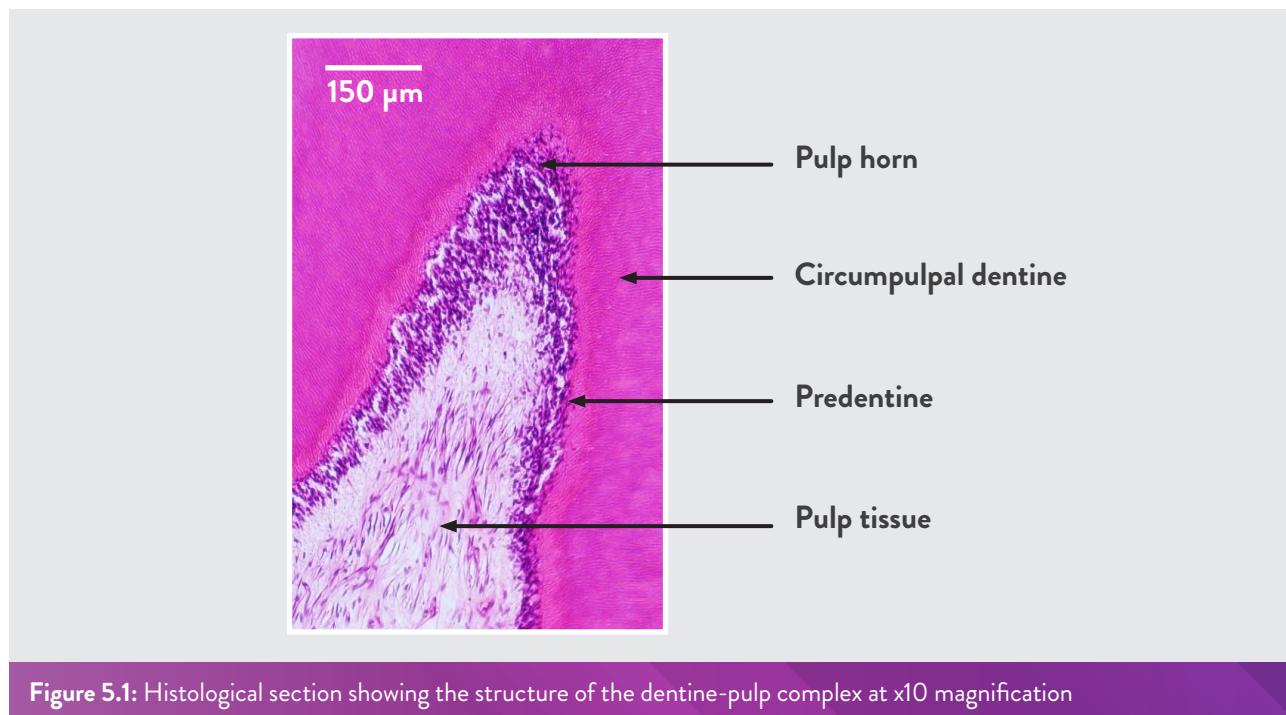


Figure 5.1: Histological section showing the structure of the dentine-pulp complex at x10 magnification

The pulp is under threat from three main sources: carious attack, trauma and iatrogenic damage (Bjørndal et al 2019). Prior to providing any definitive restoration for a tooth it is important to determine if there is any disease associated with the pulp based on the patient's symptoms and clinical examination. Classically, any inflammation associated with the pulp is termed as reversible or irreversible. These terms still remain useful but are under review as our understanding of the disease improves and clinical procedures are refined (Wolters et al 2017). Excitingly, there is emerging evidence that patients presenting with irreversible pulpitis can be definitively treated effectively with a pulpotomy (Cushley et al 2019). If this early evidence proves to be correct it will result in a paradigm shift in how we manage pulpal disease. This will mean that the current terms used for pulpal disease will be inaccurate. However, for the purpose of this document conventional terms will be maintained to avoid confusion until evidence and accepted wisdom matures.

### Current diagnostic terms for pulpal disease are as follows:

**Normal pulp:** The pulp is symptomless and responds normally to a stimulus.

**Reversible pulpitis:** Pain or discomfort initiated by a stimulus such as cold or sweet which resolves shortly after the stimulus is removed.

**Irreversible pulpitis:** More intense pain that can be spontaneous or radiating which is longer lasting and lingers after removal of stimulus.

**Pulp necrosis:** The pulp is dead and the tooth is usually unresponsive to pulp testing.

Making an accurate diagnosis of pulp status can be challenging. The information gained from an accurate patient history is supplemented with a good clinical/radiographic examination and pulp testing. It is important not to draw conclusions on one positive or negative finding and all information gathered from the exam, history and special tests should be assimilated and judged in context together (See Chapter 1).

## Strategies for vital pulp treatment (VPT)

All clinicians carrying out an operative procedure on a vital tooth should be mindful that the heat generated by dental handpieces, the potential damage by over dehydrating dentine and use of caustic agents in tooth restoration can result in unnecessary iatrogenic pulp damage. Prevention is better than cure so care and attention should be taken when removing tooth tissue or selecting materials to prevent injury to the pulp. Damage to the pulp will not just occur when the surrounding dentine is breached and VPTs should not be considered as procedures to manage the injured pulp but also thought of as a treatment step to prevent pulpal disease. The range of VPTs can be considered as follows (Duncan et al 2019) and are explored in more detail later in this chapter:

- 1. Indirect pulp capping:** The application of a material onto a thin layer of dentine which is close to the pulp with the aim of producing a positive biological response so the pulp can protect itself.
- 2. Direct pulp capping:** The application of a material directly onto the pulp with the aim of producing a positive biological response so the pulp can protect itself.
- 3. Partial pulpotomy:** The removal of a small portion of superficial coronal pulp tissue followed by the application of a material directly onto the pulp with the aim of producing a positive biological response so the pulp can protect itself.
- 4. Full pulpotomy:** Complete removal of the coronal pulp to the root canal orifice level followed by the application of a material directly onto the remaining pulp with the aim of producing a positive biological response so the pulp can protect itself.

The guidelines below cover all indications and treatment procedures to treat the vulnerable pulp irrespective of whether dentine is lost due to caries, trauma or previous iatrogenic intervention. In the case of treating caries, a strong evidence base shows that, when managing a deep carious lesion, a selective caries removal approach should be adopted (one-stage or two-stage stepwise technique) in order to decrease the risk of pulpal exposure (Schwendicke et al 2021).

Numerous different materials have been used in VPTs. The aim of using these materials is to protect the pulp and maintain its normal function. In order to do this the primary properties of such materials include:

- Antibacterial
- The creation of a bacterial tight seal and prevention of microleakage
- The promotion of tertiary dentinogenesis and controlled hard tissue barrier formation
- Biocompatible – prevention of ‘over’ irritation and avoidance of induction of a severe inflammatory response
- Radiopaque
- Resistant to forces of displacement of any subsequent material placed over the VPT material

It is established that calcium silicate cements (CSCs) such as MTA induce a more predictable and better pulpal response compared to calcium hydroxide (Nair et al 2008). However, calcium hydroxide still produces good results and is widely available to all practitioners. CSCs are yet to establish themselves as a mainstream material used by all general dental practitioners and, although CSCs are the material of choice for VPTs, calcium hydroxide is still considered acceptable.

It is important to note - **bismuth oxide containing CSCs should not be used on anterior teeth or where aesthetics are important.** Although these materials have excellent biological characteristics there is clear evidence that such materials can discolour teeth and should be avoided completely in these situations. CSCs that do not contain bismuth oxide such as Biodentine® have not yet shown cause for concern with respect to discolouration. However, users should still be cautious as such materials have not been used for long enough to clearly demonstrate that they will not cause any form of discolouration.

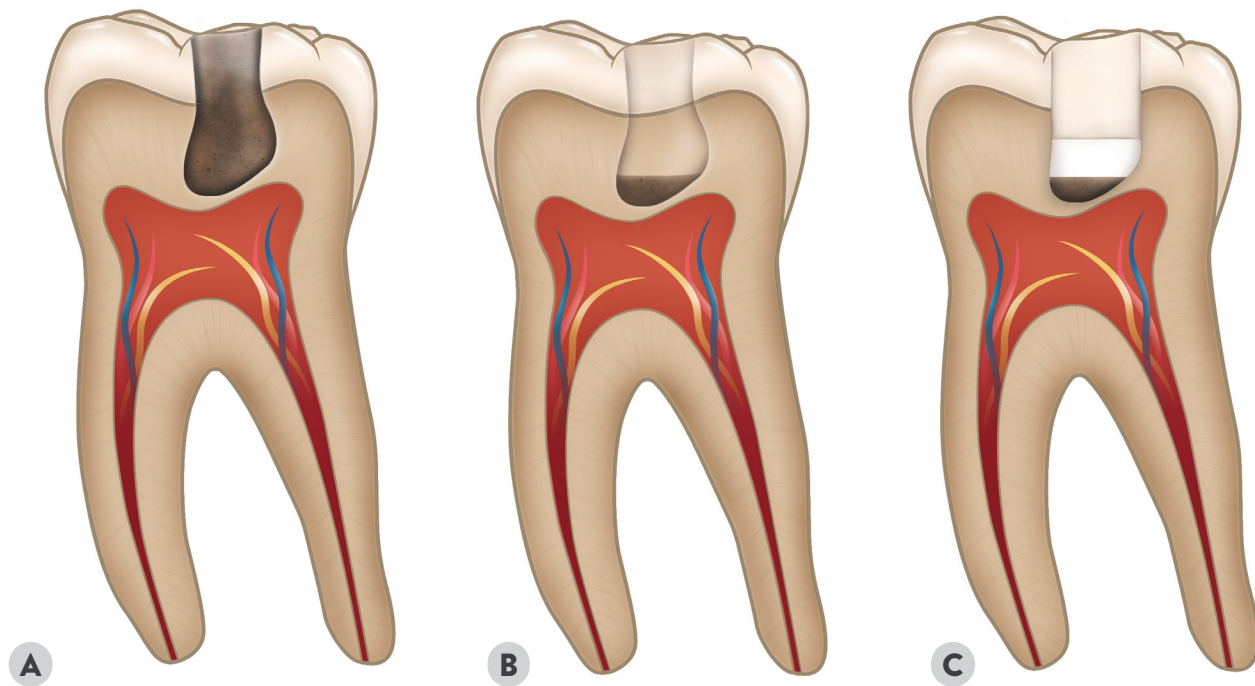
## 1. Indirect pulp capping

### Indications:

Dentine is lost due to caries, trauma or a previous iatrogenic intervention and a cavity exists which is close to the pulp but dentine still remains over the pulp tissue.

### Treatment procedure (Figure 5.2):

The tooth should be isolated with a rubber dam and the cavity preparation completed as appropriate, with attention to peripheral caries removal before carefully approaching the floor and axial wall where a pulpal exposure might be anticipated. The cavity should be disinfected using cotton pellets soaked (removing gross excess) ideally with sodium hypochlorite (0.5-5%) for 30 seconds to one minute. Having dried this, the deepest part of the cavity closest to the pulp should ideally be covered with a CSC but calcium hydroxide is suitable if an appropriate CSC is not available. If calcium hydroxide is used it should be sealed with glass ionomer cement (GIC) or a resin glass ionomer cement (RMGIC). The tooth is then definitively restored and kept under review.



**Figure 5.2:** Indirect pulp capping A) Deep carious lesion extending close to the pulp B) Cavity preparation adopting a selective caries removal approach to minimise the risk of pulp exposure C) Calcium silicate cement overlying caries with definitive restoration

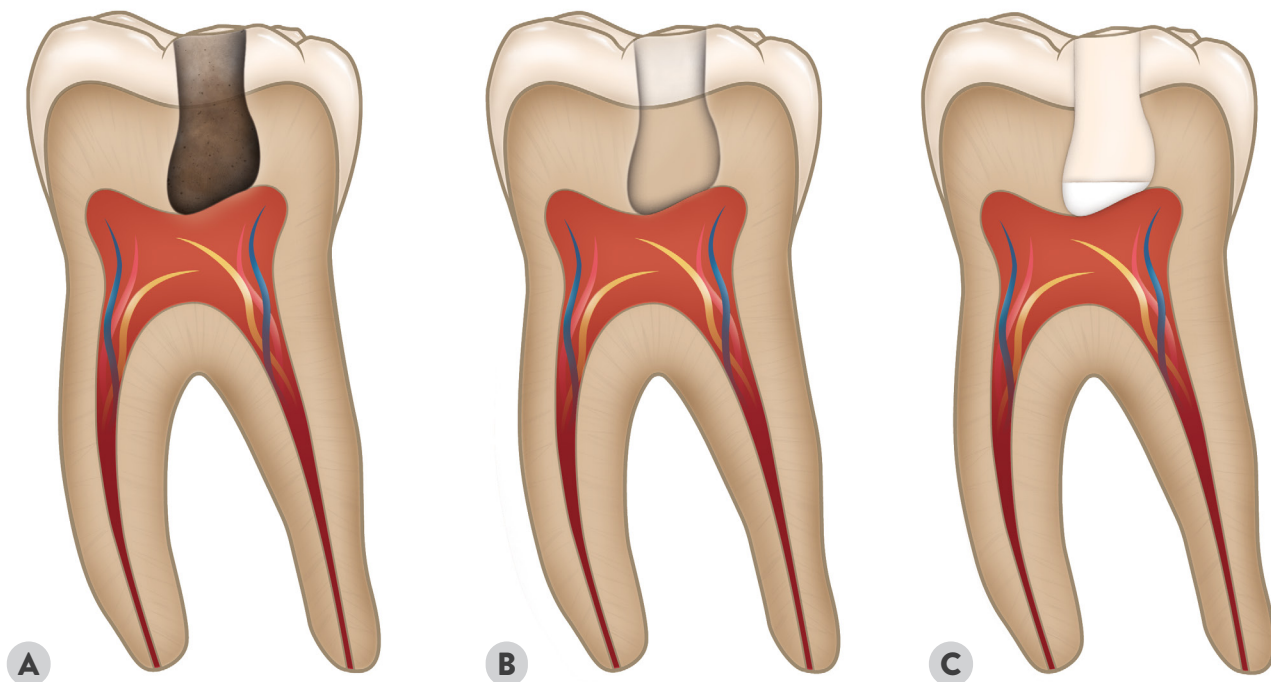
## 2. Direct pulp capping

### Indications:

Dentine is lost due to caries, trauma or a previous iatrogenic intervention and a cavity exists. However, in this case the soft tissue of the pulp is exposed and in most cases is bleeding. If symptoms exist they should be relatively mild and not considered to be indicative of irreversible pulpitis.

### Treatment procedure (Figure 5.3):

The tooth should be isolated immediately with a rubber dam. It should be disinfected using cotton pellets soaked (removing gross excess) ideally with sodium hypochlorite (0.5 -5%) until bleeding is controlled. If bleeding is not controlled within five minutes a partial pulpotomy should be carried out. The exposed pulp should be covered preferably with a CSC but calcium hydroxide is suitable if an appropriate CSC is not available. If calcium hydroxide is used it should be sealed with glass ionomer cement (GIC) or a resin glass ionomer cement (RMGIC). The tooth can be definitively restored and kept under review. The patient should be warned of the possibility of further treatment should symptoms occur.



**Figure 5.3:** Direct pulp capping A) Deep carious lesion extending to the pulp B) Carious exposure of pulp following cavity preparation C) Calcium silicate cement directly interfacing with pulp and definitive restoration has been completed

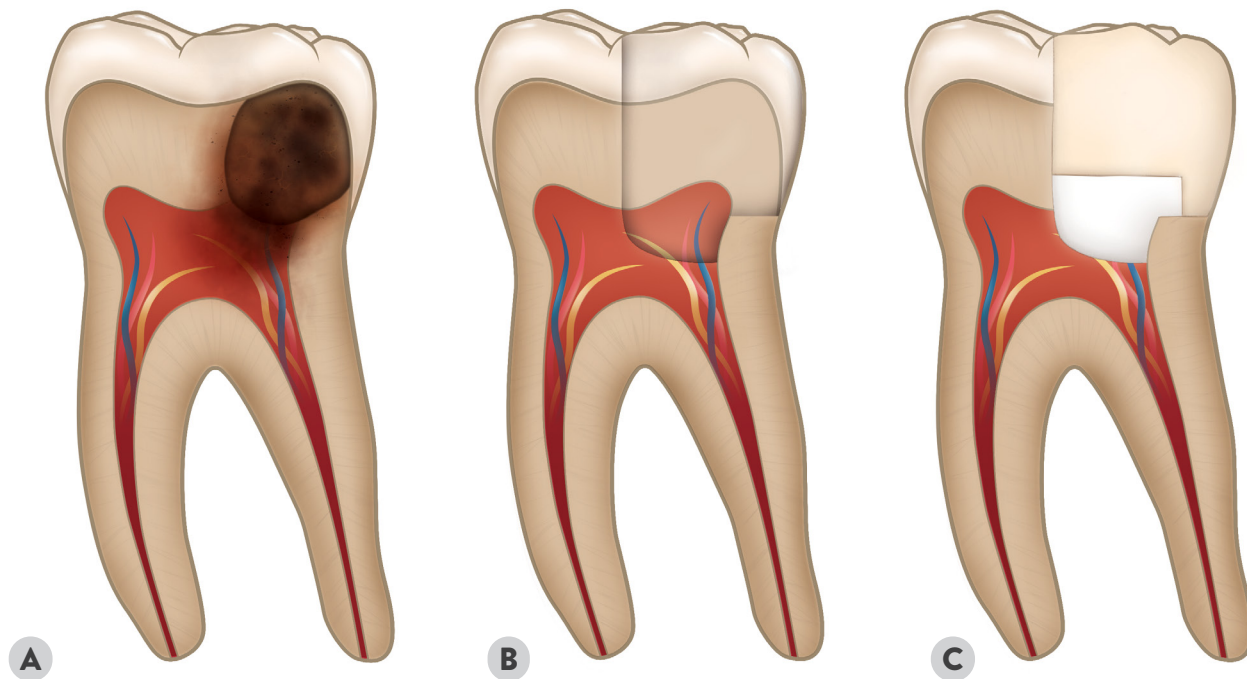
### 3. Partial pulpotomy

#### Indications:

Dentine is lost due to caries, trauma or previous iatrogenic intervention and a cavity exists where the soft tissue of the pulp is exposed and bleeding. The exposed pulp appears to be inflamed/contaminated or it is not possible to get haemostasis. Symptoms may exist.

#### Treatment procedure (Figure 5.4):

The tooth should be isolated with a rubber dam. Superficial coronal pulp tissue is removed with a high-speed handpiece, ideally with a new sterile bur and sterile saline as an irrigant and the bleeding controlled using cotton pellets soaked (removing gross excess) ideally with sodium hypochlorite (0.5 -5%). If bleeding is not controlled within five minutes further pulp tissue should be removed. A CSC is placed onto the remaining pulp tissue - however, calcium hydroxide is suitable if an appropriate CSC is not available. If calcium hydroxide is used it should be sealed with glass ionomer cement (GIC) or a resin glass ionomer cement (RMGIC). The tooth can be definitively restored and reviewed appropriately.



**Figure 5.4:** Partial pulpotomy A) Deep carious lesion extending to the pulp B) Carious exposure of pulp following cavity preparation and removal of superficial inflamed pulp tissue C) Calcium silicate cement directly interfacing with pulp and definitive restoration of the tooth has been completed

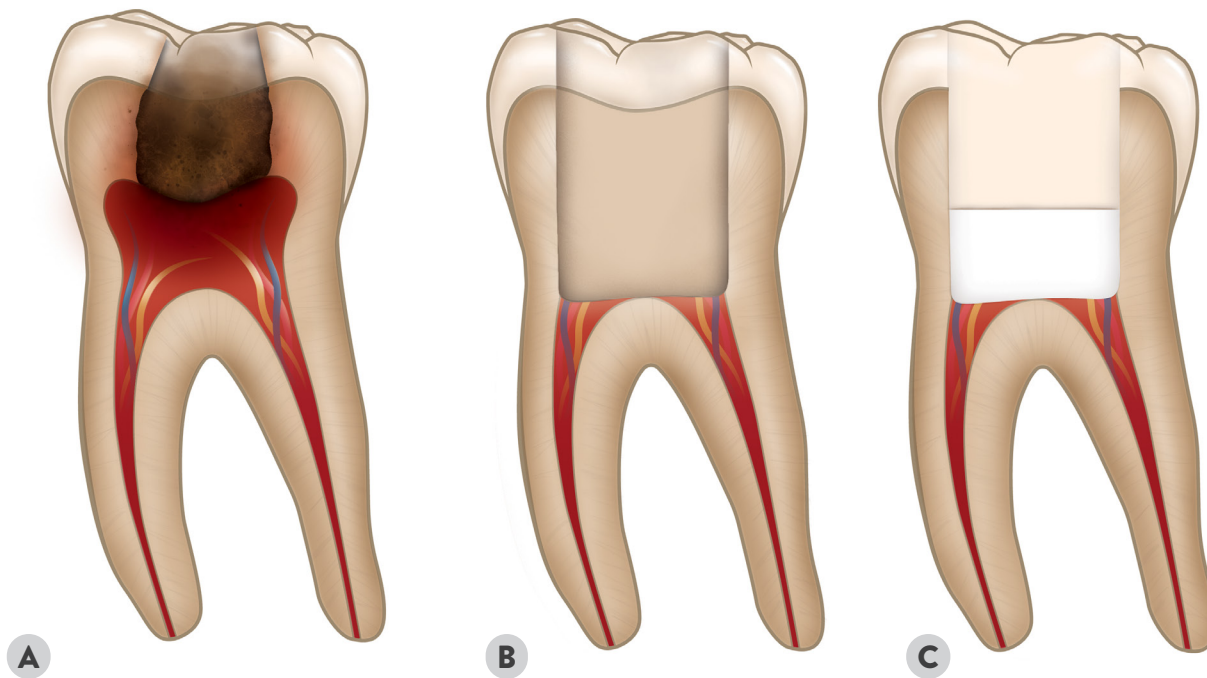
## 4. Full pulpotomy

### Indications:

Dentine is lost due to caries, trauma or previous iatrogenic intervention and a cavity exists where the soft tissue of the pulp is exposed and bleeding. The exposed pulp appears to be inflamed/contaminated or it is not possible to get haemostasis at a superficial level. Symptoms may exist.

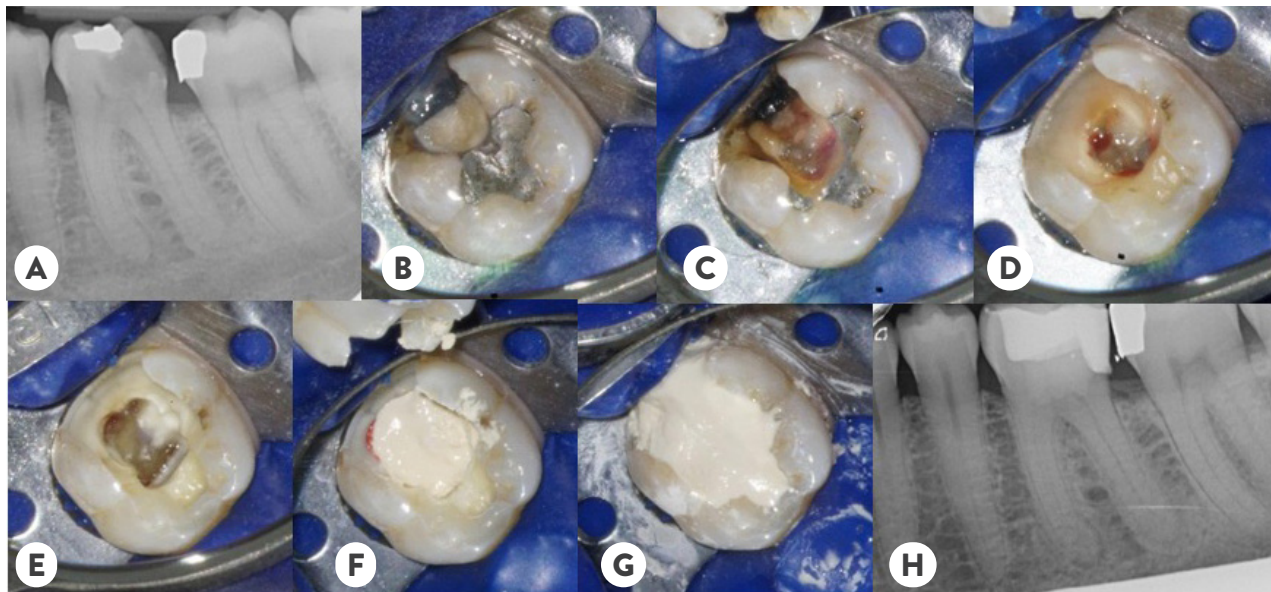
### Treatment procedure (Figures 5.5 and 5.6):

The tooth should be isolated with a rubber dam. The coronal pulp tissue is completely removed to canal orifice level with a high-speed handpiece and bleeding controlled using cotton pellets soaked (removing gross excess) ideally with sodium hypochlorite (0.5 -5%). If bleeding is not controlled within five minutes further pulp tissue should be removed until haemostasis is achieved or it is determined that a pulpectomy should be carried out. A CSC is placed onto the remaining pulp tissue. However, calcium hydroxide is suitable if an appropriate CSC is not available. If calcium hydroxide is used it should be sealed with glass ionomer cement (GIC) or a resin glass ionomer cement (RMGIC). The tooth can be definitively restored and reviewed.



**Figure 5.5:** Full pulpotomy A) Deep carious lesion extending to the pulp B) The whole of the coronal portion of the pulp is removed C) Calcium silicate cement directly interfacing with pulp stumps at the canal orifice and definitive restoration has been completed





**Figure 5.6:** Clinical case illustrating stages of full pulpotomy A) Pre-operative periapical radiograph of deep carious lesion of left mandibular first molar B) Initial carious removal C) Further caries removal showing carious exposure D) Caries removal and full pulpotomy complete. Pulp tissue bleeding from each orifice of the canal E) Haemostasis achieved F) Initial placement of calcium silicate cement (Biodentine) directly interfacing with pulp stumps G) Whole tooth temporarily restored with calcium silicate cement (Biodentine) H) Post-operative periapical radiograph with definitive composite restoration overlying Biodentine which interfaces with pulp, fills the pulp chamber and acts as a base for the definitive composite restoration

Although the diagnostic term advises otherwise, there is emerging evidence that suggests it may be possible to treat irreversible pulpitis with VPT. Therefore the appropriateness of a diagnostic terminology that dictates treatment rationale should be questioned and revised. This is an emerging area of clinical research - once the appropriate clinical trials are conducted and if it is proven that what is termed as irreversible pulpitis can be treated with VPT, it will have a huge impact on the management of endodontic disease and enable us to truly carry out minimally invasive endodontics.

### ■ Key points

- VPTs should be carried out using a rubber dam with aseptic conditions
- Safe use of sodium hypochlorite is recommended for cavity disinfection and control of haemostasis
- Any pulp tissue should be removed in a precise manner with a high-speed handpiece and diamond bur
- CSCs are the material of choice for VPTs
- Bismuth oxide containing CSCs should not be used on anterior teeth or where aesthetics are important

## Follow-up and outcomes for VPT

Following VPT, teeth should be carefully monitored by history and clinical examination at six months and a periapical radiograph at one year. If symptoms persist or there is uncertainty regarding healing, the tooth should continue to be assessed at regular intervals and a further intervention should be carried out if indicated. Cold and electric pulp testing should be carried out to monitor pulpal response, noting that teeth with full pulpotomy will be unresponsive.

VPT carried out well using aseptic techniques can produce predictable results with a high success rate. Direct pulp capping with either a CSC or calcium hydroxide at one year shows success rates of nearly 90% with partial and full pulpotomy demonstrating 98% and 99% success rates respectively at the same time point (Aguilar and Linsuwanont 2011).

### ■ Key points

- VPTs should be monitored carefully by history and clinical examination at six months with a periapical radiograph at one year
- VPTs carry a high success rate

## References:

- Aguilar P, Linsuwanont P (2011). Vital pulp therapy in vital permanent teeth with cariously exposed pulp: a systematic review. *J Endod* 37(5):581-7.
- Bjørndal L, Simon S, Tomson PL, Duncan HF (2019). Management of deep caries and the exposed pulp. *Int Endod J.* 52(7):949-973.
- Cushley S, Duncan HF, Lappin MJ, Tomson PL, Lundy FT, Cooper P, Clarke M, El Karim IA. (2019). Pulpotomy for mature carious teeth with symptoms of irreversible pulpitis: A systematic review. *J Dent.* 2019 Sep;88:103158.
- Duncan HF, Galler KM, Tomson PL, Simon S, El-Karim I, Kundzina R, Krastl G, Dammaschke T, Fransson H, Markvart M, Zehnder M, Bjørndal L, Dummer PMH (2019). European Society of Endodontology position statement: Management of deep caries and the exposed pulp. *Int Endod J.*52(7):923-934.
- Nair PN, Duncan HF, Pitt Ford TR, Luder HU (2008). Histological, ultrastructural and quantitative investigations on the response of healthy human pulps to experimental capping with mineral trioxide aggregate: a randomized controlled trial. *Int Endod J.* Feb;41(2):128-50.
- Schwendicke F, Walsh T, Lamont T, Al-Yaseen W, Bjørndal L, Clarkson JE, Fontana M, Gomez Rossi J, Göstemeyer G, Levey C, Müller A, Ricketts D, Robertson M, Santamaria RM, Innes NP (2021). Interventions for treating cavitated or dentine carious lesions. *Cochrane Database Syst Rev.* 2021 Jul 19;7(7):CD013039.
- Wolters WJ, Duncan HF, Tomson PL, Karim IE, McKenna G, Dorri M, Stangvaltaite L, van der Sluis LWM (2017). Minimally invasive endodontics: a new diagnostic system for assessing pulpitis and subsequent treatment needs. *Int Endod J.* 50(9):825-829.

Contents

Foreword

Preface

Chapter 1

Chapter 2

Chapter 3

Chapter 4

Chapter 5

Chapter 6

Chapter 7

Chapter 8

Chapter 9

# Chapter 6:

## Primary root canal treatment

**It is well established that the success and predictability of root canal treatment to prevent or cure apical periodontitis is dependent upon an accurate diagnosis and completion of each stage of treatment to a high standard. Apical periodontitis is caused by infection or injury to the pulp tissues leading to pulp necrosis and subsequent bacterial colonisation of the root canal system. Treatment is aimed at eliminating microorganisms from the root canal system and preventing reinfection with a well-sealed root canal filling and coronal restoration.**

**Four factors have been shown to significantly improve the outcome of primary root canal treatment:**

- Pre-operative absence of periapical radiolucency
- Root filling with no voids
- Root filling extending within 2mm of the radiographic apex
- Satisfactory coronal seal and restoration

The operator has no control or influence over the pre-operative status but can ensure that the presenting clinical picture is noted and taken into account when planning the treatment. It is also important to ensure that the patient is aware of the situation and its impact on the prognosis of the treatment. It is important that patient expectations are managed effectively from the outset.

**Root canal treatment for permanent teeth is indicated if any of the following clinical conditions exist:**

- Teeth with symptomatic, irreversible pulpitis (although this is being questioned – see Chapter 5) with or without evidence of periapical disease
- Necrotic pulp with or without evidence of apical periodontitis
- Teeth with a pulp that would be compromised during dental procedures, including but not limited to, overdenture abutments, malpositioned teeth and root resection
- On the rare occasion where the placement of a core, and possibly a post, is necessary for the retention of a fixed restoration

### Aims and objectives of root canal preparation

The broad objectives of root canal treatment can be considered separately as the biological and technical objectives.

#### Biological objectives of cleaning and shaping the root canal system

Pulp death and subsequent necrosis renders the root canal space undefended and provides an ideal warm and moist environment with an abundant nutrient source to support microbial proliferation. Primary endodontic infections are caused by oral bacteria which are usually opportunistic pathogens. Once the root canal space is infected, endodontic microbiota exist in a fluid phase or, as dense bacterial aggregates/coaggregates adhering to the root canal walls forming multi-layered communities that resemble biofilm.

It is not possible to mechanically prepare the entire root canal system; the operator is therefore reliant on other methods of cleaning to achieve the following biological objectives:

- To disinfect as much of the root canal system as possible
- To remove any potential nutrient source that will sustain or promote proliferation of microorganisms in the root canal system
- To prevent recontamination of the root canal system

### **Mechanical objectives of cleaning and shaping the root canal system**

Cleaning and shaping are processes that are not independent of each other. Mechanically altering the shape of the root canal system facilitates cleaning in two ways: 1) it allows the direct removal of bacteria and nutrient sources from the root canal system and 2) it enables active agents that are involved in the disinfection process to penetrate deeper into the root canal system. In order to shape the canal so that cleaning and obturation can be facilitated to produce an optimal seal the following features are desired:

- **Taper** – a continuously tapered preparation should be produced
- **Canal axis** – the position of the canal axis should be maintained in the centre of the root
- **Foramen** - the original position of the foramen should be maintained and not enlarged

A continuously tapering preparation is required to deliver chemically active fluids to the canal terminus to remove and destroy bacteria that are driving the inflammatory process in periradicular disease. Sufficient space needs to be created to enable solutions to be carried to the apical part of the canal.

### **Tooth isolation**

The use of a rubber dam is mandatory for root canal treatment. If it is not technically possible to apply the dam then restorability of the tooth and the reason for carrying root canal treatment must be challenged. Debate exists over what point in the procedure to place the rubber dam: prior to access or once a reference point is determined within the pulp chamber. The latter is recommended to ensure optimal orientation to minimise the risk of iatrogenic damage, such as perforation, especially for less experienced operators. In most cases, for root treatment, single tooth isolation is recommended to reduce the number of potential sites for leakage. The use of non-latex dam is advised given the prevalence and severity of natural rubber latex allergy.

#### **A rubber dam is used to:**

- Minimise the risk of contamination of the root canal system by oral bacteria in saliva and other tissue fluids
- Prevent ingestion or aspiration of dental materials, irrigants and instruments
- Provide a controlled operative environment
- Improve visualisation of the operating field

On occasions the rubber dam does not fully adapt around the tooth. Secondary isolation by means of designated light cured resin or putty/caulk can be placed around the tooth to enhance the seal. Prior to using caustic agents such as sodium hypochlorite it is worth informing patients that they should alert the operator and/or assistant if they get a bad taste. This is because some patients may think it is normal and the opportunity to determine a poorly fitting dam may be lost.

## ■ Key points

- A rubber dam is mandatory for root canal treatment
- A non-latex rubber dam is recommended
- In most cases only place one tooth through the rubber dam for carrying out root canal treatment
- Ask your patient to alert the operator or nurse if they experience any bad tastes

## Technical phases of treatment

**Pain control:** This is achieved with local anaesthetics intended for dental use.

The commonly used agents are:

- Lignocaine hydrochloride 2% with adrenaline 1:80 000
- Articaine hydrochloride 4% with adrenaline 1:100 000 or 1:200 000
- Mepivacaine hydrochloride 3%
- Prilocaine hydrochloride 4% with octapressin

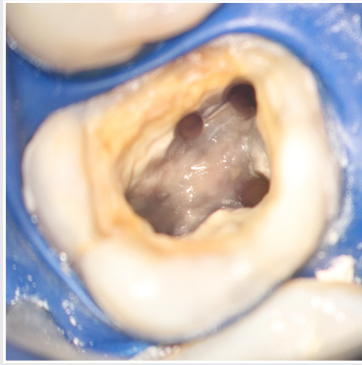
Routes of administration are local infiltrations (such as buccal, palatal and lingual infiltrations) or nerve blocks (such as inferior alveolar nerve, mental nerve, superior alveolar nerve, long buccal nerve, infraorbital nerve, nasopalatine nerve or greater palatine nerve). Variations of the inferior alveolar nerve blocks include the Gow Gates or the Akinosi techniques. For difficult to anaesthetise teeth, anaesthesia can be supplemented with techniques such as buccal infiltrations with Articaine for posterior mandibular teeth, intraligamentary injections around the tooth, intra-pulpal injections once the pulp has been accessed or intra-osseous infiltrations.

**Initial access:** Access is dictated by the size and shape of the pulp chamber and position of the canal orifices, as well as by the tooth's position in the arch. The angulation of the tooth, roots and alveolar contour provide additional information as to the likely location of the root canal(s) but the best reference point is what would be the root face at the cemento-enamel junction (CEJ).

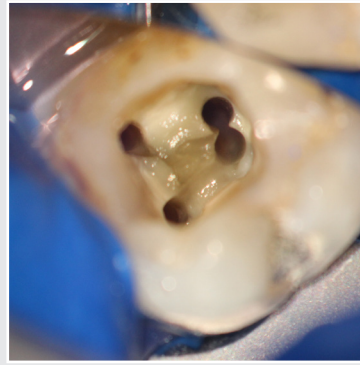
The centre of the pulp chamber should be the target of the initial penetration. The access cavity should be widened to ensure that the floor of the cavity can be seen. Controlled removal of the pulp roof can be carried out with a steel or tungsten carbide round bur by engaging the pulp roof and moving in an upward lateral fashion until it is removed. Safe ended burs can then be used to enlarge the access cavity to taper and smooth the axial walls and widen the access cavity to the periphery of the pulp chamber. The access cavity needs to be as conservative as possible, while at the same time permitting visualisation of the entire pulpal floor and allowing straight-line access into the canals.

**Canal localisation and radicular access:** To complete the access cavity, the axial walls should be smoothed and flared to ensure that no coronal dentine will impede straight-line access for instrumentation of the apical part of the canal. Canal identification can be simplified by following several key rules of root canal anatomy and the use of magnification is recommended:

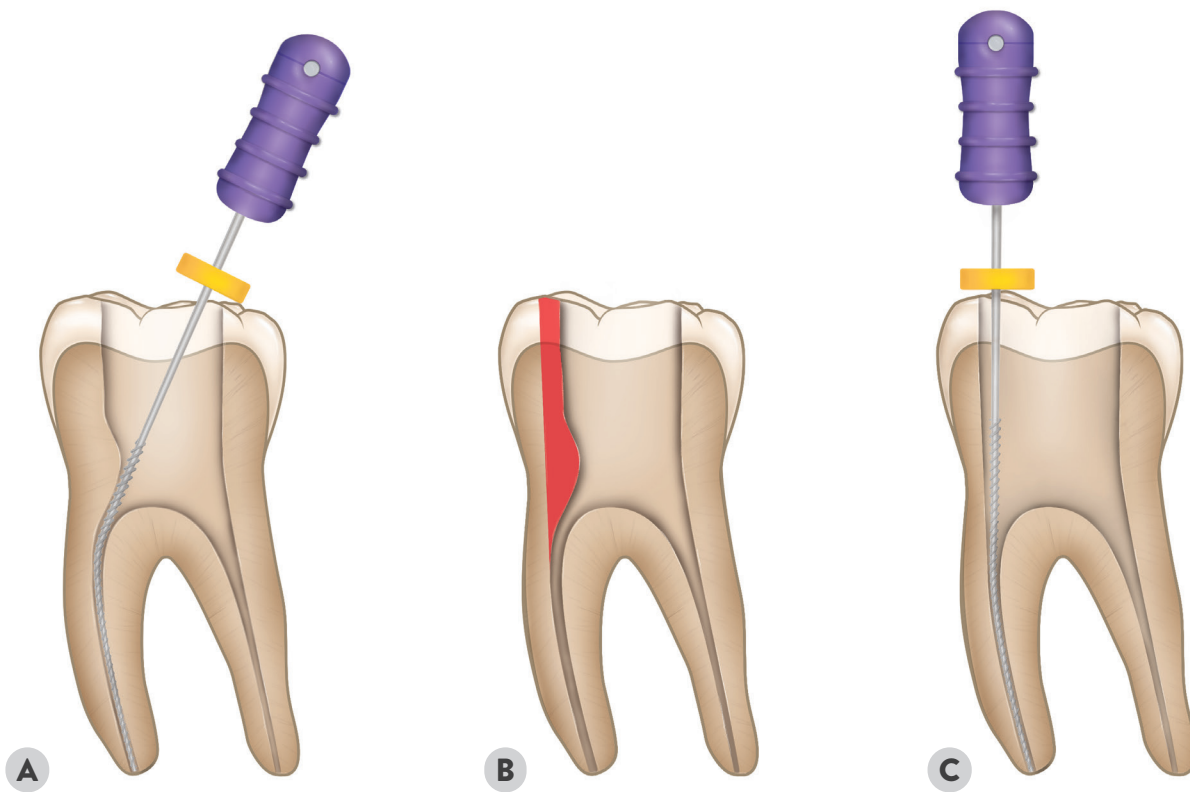
- Law of colour change - The colour of the pulp chamber floor is always darker than the canal walls (**Figure 6.1**).
- Law of symmetry - Barring maxillary molars, the orifices of the canals are equidistant and lie perpendicular from a central line drawn in a mesiodistal direction through the pulp chamber floor (**Figure 6.2**).



**Figure 6.1:** Clinical photograph of maxillary first molar following completion of root canal preparation showing clear distinction between the pulp floor (dark) and pulp chamber walls (creamy)



**Figure 6.2:** Clinical photograph of mandibular first molar following completion of root canal preparation showing symmetrical distribution of the canals



A

B

C

**Figure 6.3:** Developing straight line access – the process of removing coronal and radicular dentine (coronal third) in order to prevent deflection of the file from a straight path until it penetrates deeper into the canal A) File is deflected by coronal and radicular third dentine highlighted in B) and C) This dentine is removed and the file passes deep into the canal along a straight path without deflection



## British Endodontic Society

- Laws of orifice location one - The orifices of the root canals are always located at the junction of the walls and the floor.
- Laws of orifice location two- The orifices of the root canals are located at the terminus of the developmental root fusion lines (DRFL), commonly known as the dentine map or grey tracks. The radicular aspect of the pulp can only safely and predictably be accessed once the coronal interferences have been removed (**Figure 6.3**).

**Canal negotiation and glidepath creation:** Canal negotiation and glidepath creation can frequently be the most difficult stage in root canal therapy. In order to prevent iatrogenic errors such as the creation of blockages, ledges and perforations, the operator should take a methodical approach. To prepare a root canal, an initial pathway has to be negotiated for other instruments to follow. In aeronautical terms, the word 'glidepath' means 'the approach path of an aircraft when landing, usually defined by a radar beam'. In endodontics, this word has been adopted with a similar interpretation. The glidepath is a smooth unimpeded pathway or 'approach' from the coronal orifice of the canal to its terminus at the anatomical foramen to allow larger instruments to follow. To create a glidepath in narrower, tight, calcified canals, a systematic approach is advised, with small, stainless steel hand files (sizes 6, 8, 10) used in a watch-winding fashion to start opening the canal. Larger stainless steel hand files can be used subsequently (sizes 15, 20, 25 and so on) to follow the traditional pre-flare technique. However, due to the significant sequential increase in tip size and reduced flexibility of these files, caution should be exercised in more challenging canals. Specific engine driven Nickel-Titanium (NiTi) files have been developed to do some of this work - however initial negotiation still has to be made with a manual stainless steel instrument.

**Canal shaping:** The crown-down technique is widely accepted as the preferred approach to canal preparation. This entails sequentially widening the canal from a coronal to an apical direction. Whilst early in the shaping of the canal it is important to get straight-line access, typically, in multi-rooted teeth this means removing dentine to eliminate any curvature in the coronal part of the canal. This is so that subsequent files entering the apical region have straight-line access and an unimpeded pathway to the apical part of the canal. This crown-down approach allows for bulk removal of infected material early in the preparation. It will reduce stress on subsequent instruments used deeper in the canal and facilitate better irrigant exchange.

A myriad of different techniques exist to prepare and shape a root canal and there is no evidence that one is better than the another. A large proportion of practitioners use NiTi files as they offer many advantages compared to stainless steel files such as: flexibility, elasticity, improved resistance to cyclic fatigue and generally a quicker technique.

When using engine driven NiTi files, the following principles should be followed:

- Straight-line access should have been established
- NiTi files are for canal enlargement and not negotiation
- A glidepath should have been established prior to file insertion
- The canal should always be lubricated with irrigant
- An electric speed and torque control motor should be used
- Minimal apical pressure should be applied to the files

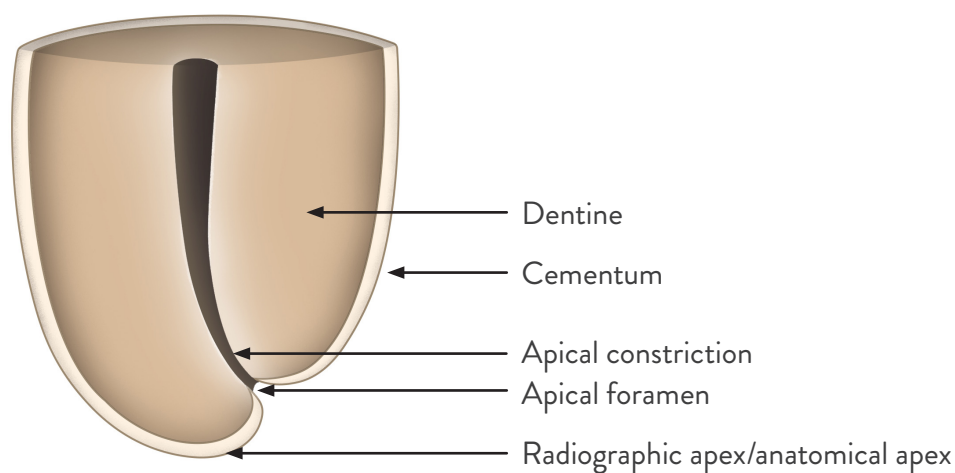
Engine driven files should be used according to the sequence and settings outlined by the manufacturer. All endodontic files are single use.

**Length determination:** Canals need to be cleaned and shaped close to their terminus or within the anatomical form known as the apical constriction (**Figure 6.4**). The length of the canal is best determined

using an electronic apex locator (EAL). This will identify the point at which the dead space of the canal transitions to the periodontal ligament just beyond the foramen. Inaccurate determination of working length may lead to short or overextended obturation. Short working length may result in retained necrotic tissues (nutrient source) which will continue to drive infection within the canal and overextended working length may result in irritation to the apical tissues. The length of the canal is determined using a combination of methods which can include: average length, estimating the length from the preoperative radiograph, tactile feedback with hand files, the use of paper points, working length radiograph and most importantly an EAL.

**Canal patency:** Establishing apical patency is a technique whereby the apical portion of the canal is maintained free of debris by recapitulation with a small file through the apical foramen. In essence, once the apical portion has been negotiated and a glidepath has been established, a small file (sizes 6, 8, 10) is passed slightly beyond the confines of the canal and through the foramen by 1mm. This should be done after each instrumentation of the canal. It is frequently misunderstood, but by definition, to use an EAL correctly, the canal has to be patent. Using a patency technique is thought to reduce the risk of accumulation of debris and soft tissue in the apical portion of the canal and therefore decreases the risk of procedural error. It is also suggested that the mechanical action of a patency file may help remove bacteria that are present in the apical constriction and foramen. When using a patency technique it must be emphasised that only small instruments should be used and they should not be extended greater than 1mm beyond the confines of the canal. Violation of this principle can lead to over-instrumentation, enlargement or transportation of the foramen, extrusion of infected debris and mechanical trauma to the apical tissues.

**Irrigation:** Irrigation has several important functions, which may vary according to the irrigant used. Primarily, it has an active function such as being antibacterial or has tissue dissolving capabilities. As a solution it will also reduce the friction between the instrument and dentine, improves the cutting effectiveness of the files, cools the file or tooth, and furthermore, it has a washing effect to flush out debris. Irrigation is also the only way to impact those areas of the root canal wall not touched by mechanical instrumentation. An active antibacterial agent should be used such as a stabilised sodium hypochlorite solution at a concentration of 0.5% to 5.25%. Other endodontic irrigants include 17% EDTA and 2% Chlorhexidine (Note: 0.2% Chlorhexidine which is sold as mouthwash is not considered



**Figure 6.4:** A diagrammatic representation of the cross-section of a root end showing basic anatomical features

## British Endodontic Society

an appropriate antibacterial agent for endodontic use). EDTA is a chelating agent and used to remove the smear layer. Chlorhexidine is a cationic solution which has a wide range of antimicrobial activity and unique feature called substantivity, which is the ability of an antimicrobial agent to retain its effectiveness for an extended period. All irrigants can be enhanced using dynamic agitation, ultrasonic activation, negative pressure irrigation or with heat.

**Apical preparation:** Using an appropriate instrument, the aim of apical preparation in most cases should be to slightly enlarge the size of the natural canal and mill a shape at the end to a known size (**Figure 6.5**). This will remove infected dentine close to the terminus of the canal and create some resistance form to aid obturation. If the canal is naturally large, for instance in a case with an immature root, no enlargement or preparation may be necessary. However, files may still be used to enhance cleaning rather than shaping per se. Ensuring that the canal is enlarged slightly at its end can be done in one of two ways. Firstly, the natural size of the canal should be determined at working length through a process called apical gauging. The other method is to closely inspect the flutes of the files when doing apical preparation after use to see if any dentine debris is trapped in the flutes right at the end of the instrument. If there is, this will mean that the instrument has cut dentine at the point at which it has penetrated in the canal.

**Obturation:** The aim of obturation is to establish a fluid-tight barrier to protect the periradicular tissues from microorganisms that reside in the oral cavity. The establishment of a well obturated system would serve three main functions:

- Prevent coronal leakage of microorganisms or potential nutrients to support their growth into the dead space of the root canal system
- Prevent periapical or periodontal fluids percolating into the root canals and feeding microorganisms
- Entomb any residual microorganisms that have survived the debridement and disinfection stages of treatment, in order to prevent their proliferation and pathogenicity

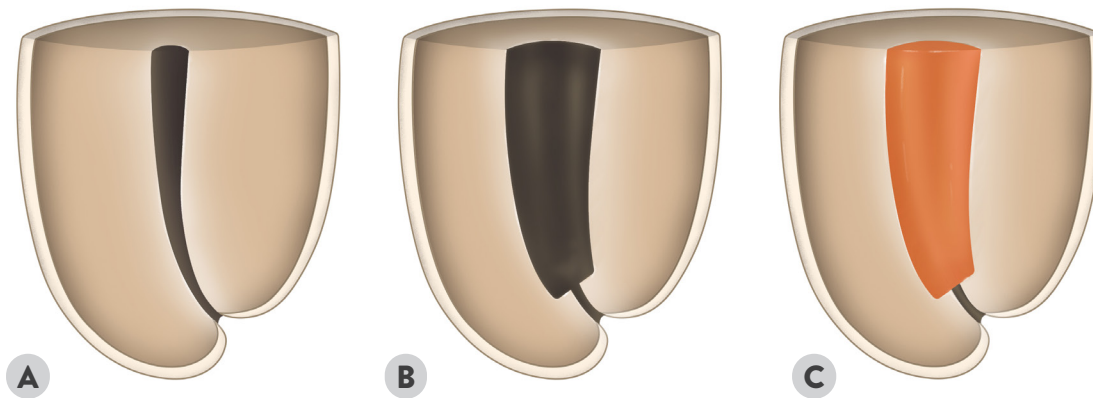
Root canal sealers are used in conjunction with a biologically acceptable semi-solid obturating material such as gutta-percha to establish an adequate seal of the root canal system. The root canal systems need to be three dimensionally obturated.

### ■ Safety considerations:

- Sodium hypochlorite needs to be safely used as extrusion can cause a hypochlorite accident (more details can be found in Chapter 9 - Management of a sodium hypochlorite accident)
- The risk can be reduced by using a side venting needle, using a finger rather than thumb pressure, never locking the needle in the canal, not advancing the needle to full working length and careful pre-operative assessment to identify open apices or perforations

Techniques include:

- Cold lateral condensation
- Warm vertical condensation
- Single cone and calcium silicate-based sealers
- Carrier based gutta-percha with sealers
- Bulk calcium silicate cements (immature apex)



**Figure 6.5:** A diagrammatic representation of a cross-section of a root end showing: A) unprepared canal, B) prepared canal and C) obturated canal

### ■ Key points

- Rubber dam isolation is mandatory
- Consider the external shape of the tooth at the CEJ in order to determine the location of the pulp chamber
- Be mindful of the colour and texture of dentine when removing it in order to locate canals
- Straight-line access to all canals minimises intraoperative complications
- Root canal systems are chemo-mechanically debrided using files and 0.5%-5.25% NaOCL
- Use an EAL to aid length determination of the canal
- Canals should be ideally obturated to the apical constriction with GP and sealer
- Pre-operative and post-operative periapical radiographs are mandatory. Mid-operative radiographs should be considered

## References

ESE (2006) Quality guidelines for endodontic treatment: consensus report of the European Society of Endodontology, *Int Endod J* 39: 921-30.

Hulsmann M, Peters O A, Dummer P M (2005) Mechanical preparation of root canals: Shaping goals, techniques and means. *Endodontic Topics* 10: 30–76.

Kakehashi S, Stanley HR, Fitzgerald RJ (1965) The effects of surgical exposures of dental pulps in germ-free and conventional laboratory rats. *Oral surgery, oral medicine, oral pathology, oral radiology, and endodontics* 20: 340-9.

Krasner P, Rankow H J (2004). Anatomy of the pulp-chamber floor. *J Endod* 30: 5–16.

Moller AJ, Fabricius L, Dahlen G, Ohman AE, Heyden G. (1981) Influence on periapical tissues of indigenous oral bacteria and necrotic pulp tissue in monkeys. *Scandinavian journal of dental research.* 89: 475-84.

Contents

Foreword

Preface

Chapter 1

Chapter 2

Chapter 3

Chapter 4

Chapter 5

Chapter 6

Chapter 7

Chapter 8

Chapter 9

# Chapter 7:

## Non-surgical retreatment

**Retreating a diseased root filled tooth aims to eliminate the cause of failure of the initial endodontic treatment and ideally achieve periapical healing. Failure may arise due to recurrence of intracanal infection as a result of:**

- Poor aseptic control during treatment e.g. treatment without a rubber dam
- Inadequate chemo-mechanical preparation and obturation i.e. inability to shape the canal(s) to working length, poor disinfection protocols and suboptimal root fillings. Even in adequately root filled teeth, intra-radicular infection can persist in the complex apical root canal anatomy. Bacteria in these locations are primarily organised as biofilms - adhesive structures of microorganisms embedded in a polymeric complex
- A breakdown of coronal seal, resulting in microleakage e.g. chipped cusp or restoration, loss of crown and defective crown or filling margin
- Procedural errors including separating instruments and perforations
- Presence of resistant microorganisms such as *E. Faecalis*

Current guidelines by the European Society of Endodontology (ESE 2006) recommend judging the outcome of root filled teeth at least one year post-treatment through clinical and radiographic examination. The outcome may be determined as:

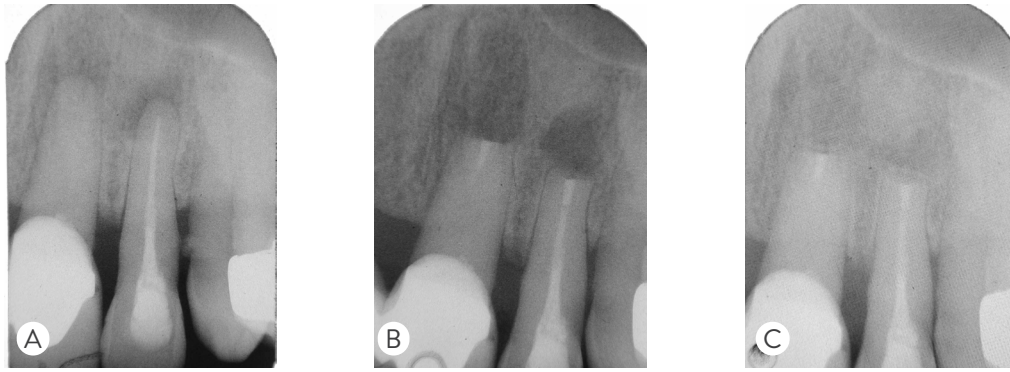
- **Favourable** - clinical and radiographic normality (**Figure 7.1**)
- **Uncertain** - occurrence of vague irreproducible symptoms and mild discomfort clinically, and no changes or a reduction of lesion size radiographically. Such lesions should be monitored until resolution or for a minimum of four years (**Figure 7.2**)
- **Unfavourable** - persistence of apical periodontitis clinically; a radiolucency that may be new, increasing in size or persistent (after four years); or signs of external inflammatory root resorption (**Figure 7.3**)

Further treatment is indicated for root filled teeth with an unfavourable outcome. This may mean retreatment, apical surgery or extraction.

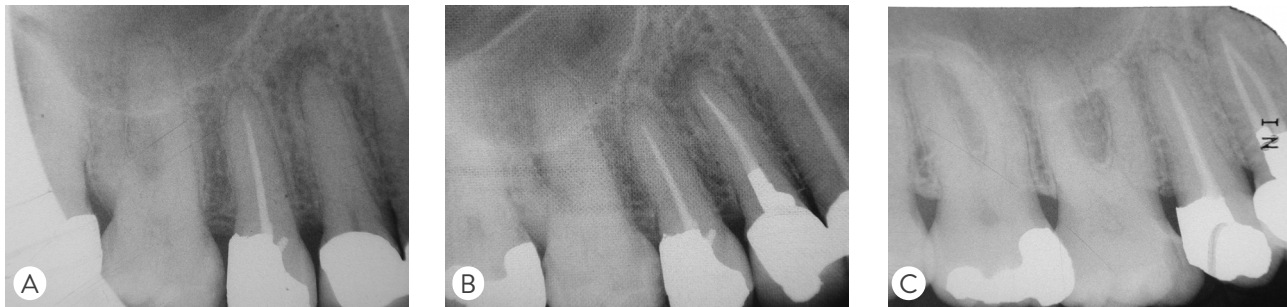The prognosis of retreatment, after two to four years following treatment, is estimated to be 80% (Ng et al 2011a). Therefore it may be a viable treatment option if the tooth is to be retained or where its removal is contraindicated e.g. patients on IV bisphosphonates or antiangiogenic medications. Retreatment may also be performed electively for cases with suboptimal root fillings that require a new coronal restoration.

For cases where retreatment has a poor prognosis, such as those where the initial treatment was carried out to a high standard, or cases where there may be a high risk of procedural errors or root fracture, e.g. as a result of blocked apical canal, sclerosed canal, inaccessible perforations, or presence of a large immovable post, apical surgery may be more appropriate (See *BES/RCSEng Guideline for Periradicular Surgery*. [www.rcseng.ac.uk/-/media/files/rcs/fds/publications/periradicular\\_surgery\\_guidelines\\_2020.pdf](http://www.rcseng.ac.uk/-/media/files/rcs/fds/publications/periradicular_surgery_guidelines_2020.pdf)).

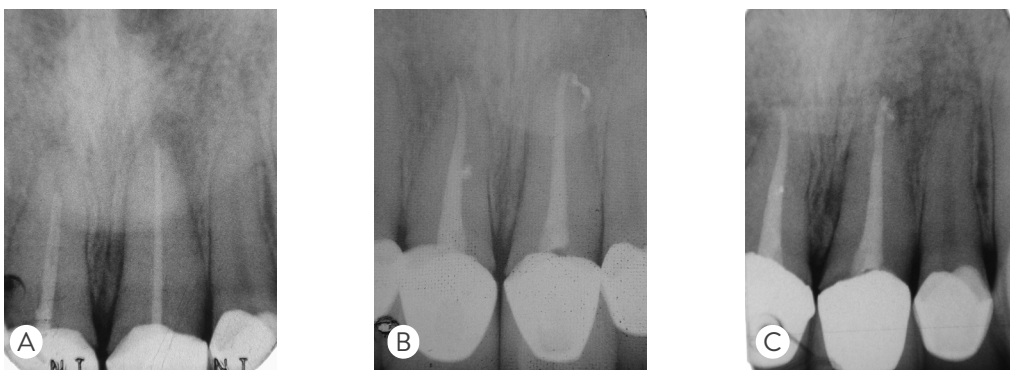
Extraction may be necessary in cases where the survival of root filled teeth is poor as a result of gross tooth tissue loss, periodontal disease, unrestorable longitudinal tooth fractures or extensive resorption. Occasionally, teeth with poor prognoses and large periapical lesions that are due to be replaced by dental implants may be retreated prior to extraction to permit alveolar bone regeneration.



**Figure 7.1:** Series of periapical radiographs showing favourable healing: A) left maxillary central and lateral incisors with apical periodontitis B) Immediate post-op following apicectomies C) 20 months post-op showing complete healing of periradicular tissues



**Figure 7.2:** Series of periapical radiographs showing uncertain healing: A) right maxillary first premolar with apical periodontitis B) Immediate post-op following root treatment C) 24 months post-op showing reduction in size of lesion but not complete resolution



**Figure 7.3:** Series of periapical radiographs showing unfavourable healing: A) maxillary central incisors with apical periodontitis B) Immediate post-op following non-surgical retreatment C) 24 months post-op showing persistent periapical lesion associated with the left maxillary central incisor



## Pertinent issues to identify in the examination and diagnosis of the previously root treated tooth

### Presentation

Root filled teeth with symptomatic apical periodontitis can present clinically with a wide range of signs and symptoms including mild to severe pain, swelling and sinus tract discharge. Asymptomatic failures may be detected radiographically as incidental findings or during outcome assessments at recall visits.

### Patient history

An accurate and detailed patient history is important; it may help to establish the cause of failure, highlight medical conditions that may affect treatment planning and help to assess the prognosis of treatment. Therefore, in addition to recording the presenting complaint, medical, dental and social histories (see Chapter 1: *Examination and diagnosis*), the patient should be asked specific questions about previous root canal treatment. Although many patients may not recall the detail, they may be able to answer some of these questions:

- When was the tooth root filled?
- Where was the treatment performed?
- How many visits did the treatment take?
- Can they remember whether a rubber dam was used?
- When was the tooth last reviewed radiographically?

### Clinical examination

The overall assessment is considered in Chapter 1: *Examination and diagnosis* but particular attention must be paid to determining if there is sufficient coronal tooth structure (minimum 2mm of circumferential supra-gingival dentine and >30% of the original coronal tooth structure remaining) to be deemed restorable (Chapter 8: *Restoration of the endodontically treated teeth*). However, if the tooth is to serve as a space maintainer, overdenture abutment, or there are medical contraindications to extraction, retreatment can be performed as long as an aseptic environment can be maintained during treatment.

### Radiographic examination

To help with diagnosis, prognosis and treatment planning of the root filled tooth, a thorough radiographic assessment is required. Apart from making an assessment of root canal morphology and presence or absence of periradicular radiolucency it will help determine:

- Presence or absence of procedural errors - missed canals, canal transportation, ledges, perforation and separated instruments
- Quality of the obturation - extent of the root canal filling, presence or absence of voids and root filling material
- Quality of the coronal seal - presence of subseal, type of coronal restoration, marginal integrity, presence or absence of caries

### Diagnosis

Once a diagnosis is made (see Chapter 1: *Examination and diagnosis*) it is wise to try and determine the cause of failure. This will help to establish whether an improvement on the primary treatment can be made in order to develop the most predictable treatment strategy.

## Decision making – treat or refer?

Dental practitioners must be able to determine the prognosis of endodontic cases and recommend relevant treatment options or seek specialist advice based on the above findings. To help patients make an informed decision on a treatment pathway, case difficulty assessment tools should be used (Chapter 2: *Case difficulty assessment and knowing when to refer*).

### ■ Key points

- Endodontic failures can be symptomatic or asymptomatic
- Noting history may help to highlight any procedural weaknesses from the previous treatment to help determine the cause of failure
- A thorough clinical and radiographic examination will help to reach an accurate diagnosis and determine the level of complexity for retreatment
- Practitioners should stay within their level of competencies and refer when necessary

## Treatment procedure

The sequential steps for retreatment are described below.

### Re-establishment of access

In order to re-establish access, the coronal restoration must be removed or accessed safely. Permanent occlusal fillings can be removed conventionally if the original access cavity was prepared sufficiently.

Indirect restoration (onlays or crowns) may require removal if they are defective or the core requires investigation. Removal, utilising levering equipment or forceps, risks tooth fracture and must be done cautiously by an experienced operator. A temporary onlay or crown should be placed afterwards to facilitate dental dam placement and/or subsequent temporisation.

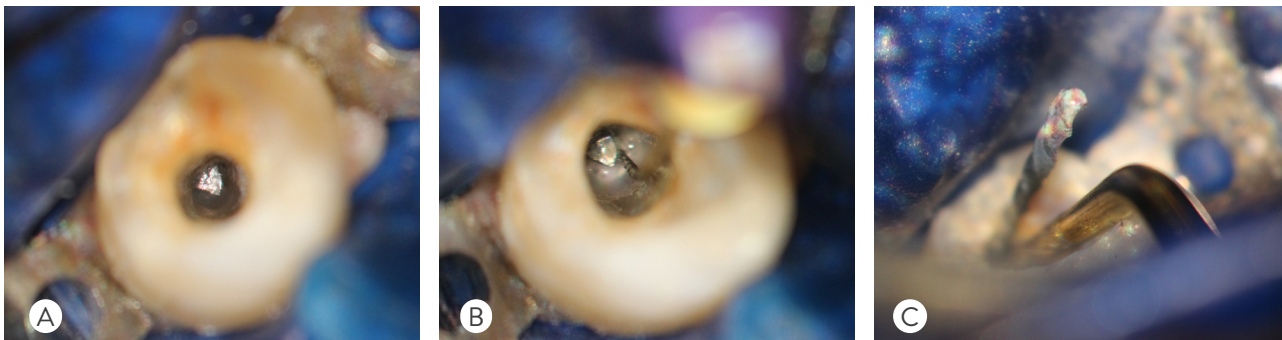
If the onlay or crown was recently placed or has sound margins, removal may not be necessary and access can be achieved through the restoration using diamond and tungsten carbide burs to cut through porcelain and/or metal respectively. Prior to executing treatment, a thorough plan must be made with attention to detail to prevent perforations and cracking / chipping of the porcelain restorations. Before accessing through any ceramic restoration it is important to warn the patient of potential cracks or fractures - especially if it could result in deterioration of aesthetics or function. It is important that the patient is made aware of these risks and that such discussions are documented clearly in the clinical records. Teeth that are crowned to restoratively mask malposition, rotation or inclination should be referred or managed with great caution to prevent occurrence of procedural errors.

Removal of intra-pulpal core material close to the pulpal floor or cavity walls may safely be completed using ultrasonic tips or long neck burs. However, if post cores or intra-radicular cores are present then these cases should also be referred, especially if the operator has limited experience or training in managing such cases.

## Removal of intracanal obstructions and negotiation of pre-operative procedural errors

Failure to achieve apical patency or instrument the root canal to its full length may result in a poorer prognosis for the retreated tooth. Therefore, the removal of intracanal obstructions and negotiation of pre-operative procedural errors is important.

In teeth with intracanal obstructions such as hard pastes, separated instruments, silver points or posts, removal may be achieved using specialised equipment. Such treatment, along with the management of procedural errors, perforations, ledges, apical transportation, over-extended obturations and canal blockages are best performed with an operating microscope (**Figure 7.4**). Unless the operator has prior experience, sufficient training and the appropriate armamentarium, cases requiring the removal of intracanal obstructions and/or management of pre-operative procedural errors should be referred.



**Figure 7.4:** Series of clinical images showing removal of separated instrument with an operating microscope. A) Visualisation of separated instrument in the root canal B) Negotiating along the side of the instrument with hand file to create some space C) Vibration of the instrument out of the canal with an ultrasonic instrument

## Removal of obturation material

The removal of obturation material permits apical patency and chemo-mechanical preparation of the entire length of canal, which improves the prognosis. Instruments often used during retreatment include stainless steel files (K-type and Hedstrom files), nickel-titanium (NiTi) rotary or reciprocating files and ultrasonic tips. These are supplemented with the use of chelating solutions and/or solvents.

Ultrasonic tips generate heat and plasticise gutta-percha. Solvents (Eucalyptol or Xylene) will dissolve hard obturation material before using hand or automated instruments in an attempt to remove them. Solvents are toxic to periapical tissue and should be used with caution.

The use of Gates-Glidden (GG) burs to remove hard obturation material may result in deflection of the instrument and potential perforation. Therefore the judicious use of ultrasonic tips or solvents is preferable to soften the material beforehand. The bulk of the obturation material is removed using hand or automated NiTi files. Hand instruments should be used to help guide NiTi rotary or reciprocating files in a crown-down method during bulk removal of material. To reduce the risk of procedural errors including file separation, files must be used prudently and their flutes should be cleaned after each use. The instrumentation should be supplemented by copious irrigation with a chelating solution, such as 17% ethylenediaminetetraacetic acid (EDTA). This will help to dissolve sealers and inorganic constituents of the root canal wall; thereby facilitating the removal of obturation material and opening of blockages (Zehnder and Paqué 2008). After the crown-down removal of the root filling material is completed, a confirmatory periapical radiograph may be taken to assess for the presence of gutta percha tags. Hedstrom files and solvent may be used to help remove these if present.

In consideration of additional complexity factors, an inappropriate choice or technique may lead to removal of unnecessary radicular dentine. This will result in weakening of the tooth and/or perforation or extrusion of the obturation material into the periapical tissues. Therefore, unless the operator is experienced, cases with flush and well-condensed obturations, over-extended obturation, silver points and gutta-percha carriers should be considered for referral.

## Chemo-mechanical preparation, disinfection, obturation and restoration

Chemo-mechanical preparation and disinfection of the radicular space to the canal terminus is achieved using NiTi shaping files and NaOCl irrigation, which follows a similar protocol to that of initial treatment. The effectiveness of NaOCl disinfection may be enhanced with the use of automated devices or manual agitation with a master cone.

Following completion of chemo-mechanical preparation and disinfection, the radicular space can be dried and obturated and restored by following the same techniques and utilising the same materials as initial treatment. However, care should also be observed during the obturation phase as the incidence of cracks is higher in teeth undergoing retreatment (Capar et al 2015). Cuspal coverage restorations capable of providing a good coronal seal and resistance to fracture are important for the long-term prognosis of retreated teeth (Ng et al a, b).

## Follow up and outcome

Complexity of retreatment cases vary and, generally, they have a reduced prognosis compared to initial root canal treatment. As per the ESE guidelines (2006), retreated root filled teeth should be clinically and radiographically assessed at least one year post-treatment and, if complete healing is not evident, annual reviews for up to four years should continue. An exception to this is the healing of large lesions that may take longer. Should an unfavourable outcome occur, apical surgery or extraction may have to be considered.

### ■ Key points

- Retreatment involves the re-establishment of access, removal of obstructions such as posts and obturation material and negotiation of pre-operative procedural errors
- Removal of root filling material and any obstructions relies on a combination of instrumentation techniques, chelating solutions, irrigants and solvents
- Chemo-mechanical preparation, disinfection and obturation can be completed by following protocols similar to those of initial treatment
- For a favourable outcome, an absence of pre-treatment perforations, achievement and maintenance of apical patency, instrumentation and obturation to the canal terminus, utilisation of 17% EDTA and a good coronal restoration are desirable

## References

Capar ID, Uysal B, Ok E, Arslan H (2015) Effect of the Size of the Apical Enlargement with Rotary Instruments, Single-cone Filling, Post Space Preparation with Drills, Fiber Post Removal, and Root Canal Filling Removal on Apical Crack Initiation and Propagation. *J Endod.* 41(2):253-6.

European Society of Endodontology (2006) Quality guidelines for endodontic treatment: consensus report of the European Society of Endodontology. *International Endodontic Journal*, 39, 921–930.

Ng Y-L, Mann V, Gulabivala K (2011a) A prospective study of the factors affecting outcomes of nonsurgical root canal treatment: part 1: periapical health. *International Endodontic Journal*, 44, 583–609.

Ng Y-L, Mann V, Gulabivala K (2011b) A prospective study of the factors affecting outcomes of non-surgical root canal treatment: part 2: tooth survival. *International Endodontic Journal* 44, 610–625.

Zehnder M, Paqué F (2008) Disinfection of the root canal system during root canal re-treatment. *Endodontic Topics*, 19: 58–73.

Contents

Foreword

Preface

Chapter 1

Chapter 2

Chapter 3

Chapter 4

Chapter 5

Chapter 6

Chapter 7

Chapter 8

Chapter 9

# Chapter 8:

## Restoration of endodontically treated teeth

**A definitive restoration of a root filled tooth is the final stage of the overall treatment of a tooth that has undergone root canal therapy. It is important to remember that a root filled tooth is at risk of structural failure simply because of the loss of pulp. The reasons are as follows:**

1. The loss of the proprioceptive function that the pulp provides means that the tooth is more vulnerable to the less discriminative masticatory loads placed upon it.
2. The inevitable loss of tooth tissue volume that led to the pulp's demise and the further loss of tooth tissue volume to perform root canal treatment successfully will weaken the remaining tooth structure.

When restoring an endodontically treated tooth, the restoration should provide an effective coronal seal in order to stop reinfection of the root canal system as that would lead to biological failure. It should also restore function, aesthetics and protect remaining tooth tissue to prevent structural failure. Most research of post-treatment failure relates to biological failure and the re-emergence of endodontic disease. However, the most common reason for root filled teeth to be extracted is because of restorative complications (Fuss et al 1999) which relate to structural failure. Survival studies have shown that the main factors influencing the survival of root filled teeth are: the quantity of sound residual tooth structure (Al-Nuaimi et al 2020) and the choice of restoration (Pratt 2016). Therefore, before starting root canal treatment it is important to determine that there is sufficient tooth structure to restore the tooth and an appropriate definitive restoration can be provided.

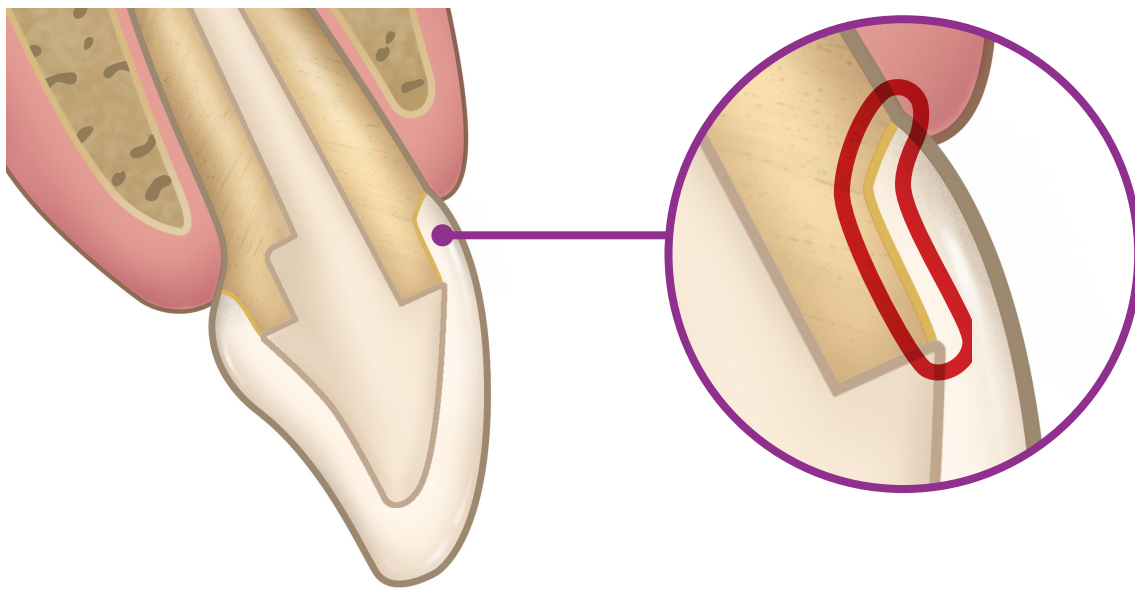
### **Summary of functions of the restoration when restoring a root filled tooth:**

- Prevention of reinfection of the root canal system
- Protection of remaining tooth tissue, structurally and from carious and non-carious attack
- Restoration of function and aesthetics
- Help maintain periodontal health

### **Remaining tooth structure – ferrule effect**

The concept of 'ferrule' or 'the ferrule effect' is a well established principle that in order to restore a tooth and predictably retain the extra-coronal restoration there must be sufficient supra-gingival dentine throughout the circumference of the tooth. This enables the margins of that extra-coronal restoration to sit on sound tooth tissue without encroaching on the biological width (**Figure 8.1**).

The biomechanical performance of the ferrule effect is well established. However there is considerable variability in clinical research into how the ferrule effect is assessed and this makes it difficult to provide specific guidance on protocols for restoring root-filled teeth. A review by Juloski et al (2012) suggested a minimum ferrule height of 1.5–2.5mm is required with a minimum thickness of 2mm (Nagasiri and Chitmongkolsuk 2005). A systematic review by Naumann et al (2018) showed that two of the three studies that qualified for analysis demonstrated the positive effect of the ferrule. Therefore clinicians should make every effort to provide an optimum ferrule when planning indirect restorations (Mannocci et al 2021).



**Figure 8.1:** Illustration of cross-section of post retained crown with magnified crown tooth tissue interface. Extra-coronal restoration margin sits onto sound tooth tissue demonstrating ferrule effect shaded in red

## Remaining tooth structure – tooth volume

Variability of clinical presentation means it can be difficult to assess the tooth's remaining structure in a standardised way and determine whether a restoration is feasible or not. More recently, due to the introduction of intra-oral scanners and CAD/CAM technology, it has become possible to quantify the remaining tooth structure as a percentage volume. This provides a much more objective way of identifying/describing/comparing clinical presentation. Early research has suggested that a remaining tooth volume of 30% is a critical threshold in terms of the predictability of a favourable or unfavourable outcome. Favourable outcomes of root treated teeth were significantly higher when more than 30% of the original tooth tissue structure was present. The converse applied if there was less than 30% (Al-Nuaimi et al 2017 and Al-Nuaimi et al 2020).

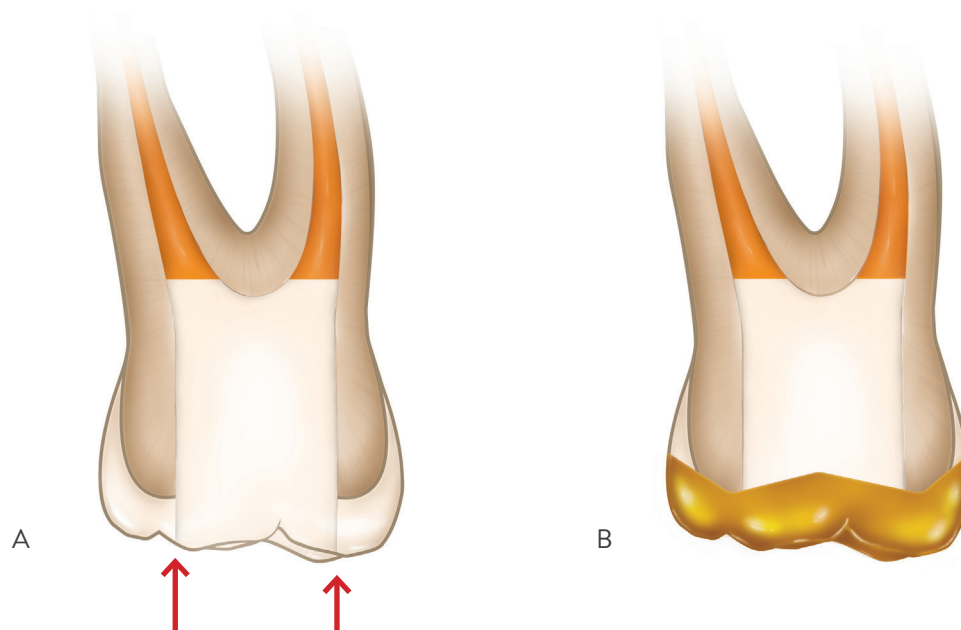
## Remaining tooth structure – proximal walls

Generally, the loss of any tooth structure weakens the tooth - however, the loss of a whole wall has a significant effect on its integrity. The analogy of a garden shed can help the patient understand the impact. The structural strength of the garden shed is based on all walls and the roof being present and fixed together firmly. Loss of any wall significantly undermines the strength of the structure. It is exactly the same for the tooth. If the tooth is weakened it is susceptible to fracture by occlusal loads.

A cuspal coverage restoration can protect a weakened tooth as follows (**Figure 8.2**):

1. It ensures there is no exposed tooth or restoration interface on the occlusal surface which would be a point of vulnerability to occlusal loading
2. It spreads the load across the whole occlusal surface
3. It prevents flexion and fracture of the residual tooth structure





**Figure 8.2:** Illustration of root filled maxillary molar in cross-section. A) Shows Class II restoration with exposed tooth/restoration interface on occlusal surface vulnerable to point loading at this interface indicated by red arrows B) Cuspal coverage restoration showing no such exposed interface

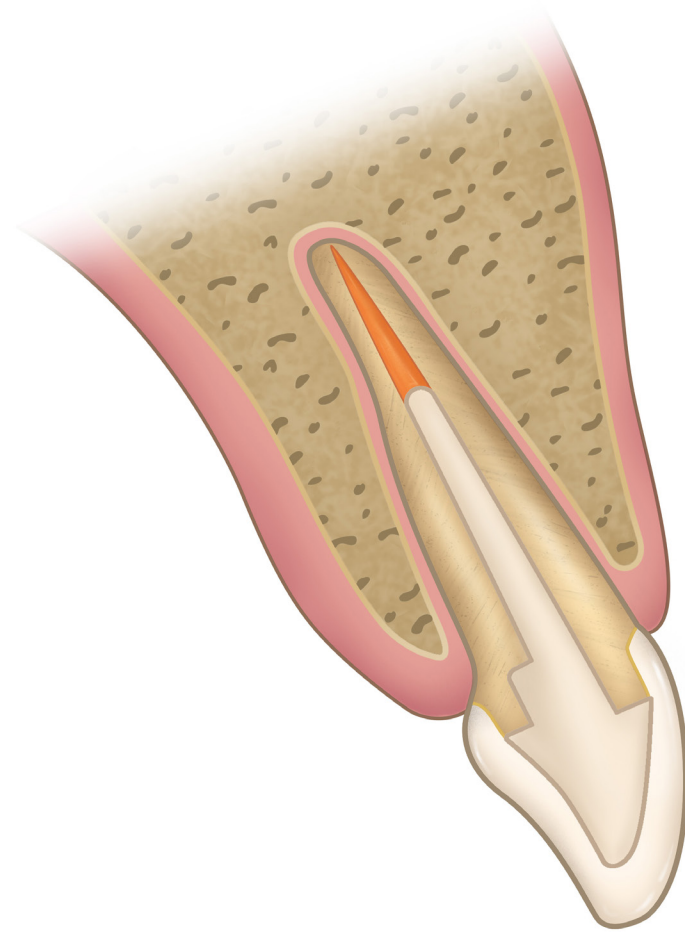
When considering restoration of a root filled tooth one of the biggest decisions to make is whether to restore with a cuspal coverage restoration or not. The guiding principles to make those decisions are as follows:

- Each case should be considered individually
- Class I cases - cuspal coverage is not likely to be required if there is adequate thickness of all remaining walls with no cracks present
- In most cases, when one proximal wall is missing in a posterior tooth, a cuspal coverage restoration will be required
- If two or more walls are missing then cuspal coverage should be used. In this case, it is better to look at it from a different standpoint and try to justify why a cuspal coverage restoration should not be utilised as circumstances will be rare
- Restorations should be designed to conserve as much sound tooth tissue as possible

## Posts

The use of posts has caused much controversy. Although every issue has not been resolved, better quality evidence has emerged in the last two decades and clearer advice can be made about their use and is summarised as follows:

- The purpose of the post is to retain the core. It is not to strengthen the root or compensate for the absence of the ferrule effect (Mannocci et al 2021)
- The choice of post material has no effect on the survival of the tooth
- With advances in adhesive technology there is no need to sacrifice further dentine to facilitate a post's placement. Posts should remain passive in the root canal space
- Post length should ideally be longer than the clinical crown it is restoring - but a minimum of 4-5mm of root filling material should be left so it does not disturb the apical seal (**Figure 8.3**)



**Figure 8.3:** Cross-section of root filled tooth restored with a post crown featuring the following design features:

- Post length is longer than crown height
- Sufficient remaining gutta-percha to maintain an apical seal
- Extra-coronal restoration sits on sound tooth 2mm beyond core material (ferrule)
- Post shape respects shape of prepared canal

## Restoration type

Cuspal protection is paramount for any premolar or molar root filled teeth that are considered vulnerable due to loss of tissue as discussed above. Outcomes for indirect onlays and crowns constructed of metal, metal ceramic, all ceramic and indirect composite are excellent. There is limited research for direct cuspal coverage restorations but the principle of providing an immediate definitive restoration with minimal tooth tissue loss in the case with a composite resin restoration seems attractive.

## Terminal or lone standing teeth

Teeth with only one proximal contact, no proximal contacts and the terminal tooth (last standing molar) are particularly vulnerable to increased risk of structural failure. It is important to pay attention to occlusal factors such as excessive occlusal forces, premature occlusal interferences and dynamic loading in excursive and protrusive guidance.

## ■ Key points

- Prior to commencing root canal treatment ensure there is sufficient tooth structure to restore the tooth
- The strength of a tooth is broadly proportional to the volume of the remaining natural tooth tissue. All efforts should be made to conserve that tooth tissue volume
- Clinicians should make every effort to provide an optimum ferrule when planning indirect restorations
- Cuspal coverage restoration is required in most cases when there is loss of one or more proximal walls of a root filled posterior tooth

## References

- Al-Nuaimi N, Patel S, Austin RS, Mannocci F. A prospective study assessing the effect of coronal tooth structure loss on the outcome of root canal retreatment. *International Endodontic Journal* 2017. 50: 1143–57.
- Al-Nuaimi N, Ciapryna S, Chia M, Patel S, Mannocci F. A prospective study on the effect of coronal tooth structure loss on the 4-year clinical survival of root canal retreated teeth, and retrospective validation of the Dental Practicality Index. *International Endodontic Journal* 2020. 53:1040–9.
- Fuss Z, Lustig J, Tamse A. Prevalence of vertical root fractures in extracted endodontically treated teeth. *Int Endod J.* 1999 Aug;32(4):283–6.
- Juloski J, Radovic I, Goracci C, Vulicevic Z R, Ferrari M. Ferrule effect: a literature review. *Journal of Endodontics* 2012. 38: 11– 19.
- Mannocci F, Bhuvra B, Roig M, Zarow M, Bitter K. European Society of Endodontology position statement: The restoration of root filled teeth. *Int Endod J.* 2021 Nov;54(11):1974-1981.
- Nagasiri R and Chitmongkolsuk S. Long- term survival of endodontically treated molars without crown coverage: a retrospective cohort study. *Journal of Prosthetic Dentistry*, 2005. 93: 164– 170.
- Pratt I, Aminoshariae A, Montagnese TA, Williams KA, Kha-lighinejad N, Mickel A. Eight-year retrospective study of the critical time lapse between root canal completion and crown placement: its influence on the survival of endodontically treated teeth. *Journal of Endodontics* 2016. 42: 1598–603.

Contents

Foreword

Preface

Chapter 1

Chapter 2

Chapter 3

Chapter 4

Chapter 5

Chapter 6

Chapter 7

Chapter 8

Chapter 9

# Chapter 9:

## Management of a sodium hypochlorite accident

One of the key steps in root canal treatment is the chemo-mechanical preparation of the root canal system in order to remove microorganisms and their by-products. The recommended chemical agents utilised for disinfection of the root canal system are sodium hypochlorite used as an irrigant, and calcium hydroxide as an inter-appointment dressing. The other irrigants used e.g. EDTA, CXD are normally considered adjuncts to sodium hypochlorite.

Some dentists are fearful of using sodium hypochlorite, perhaps because they have experienced an adverse incident on a previous occasion or because they lack the confidence to apply the rubber dam effectively. It remains the irrigant of choice because of its potent antimicrobial properties, tissue dissolving capability and low viscosity which allows it to be introduced into the root canal system easily.

Inadvertent extrusion of sodium hypochlorite beyond the end of the root into the periradicular tissues or into the oral cavity beyond the confines of the rubber dam can result in an inflammatory response, referred to as a 'sodium hypochlorite accident'. It is an unintentional incident, hence the term 'accident'.

There have been very few cases of true allergic reactions to sodium hypochlorite and these cases will have presented with swelling, difficulty breathing, urticaria, oedema and hypotension in line with anaphylaxis. The management of these cases should follow medical emergency procedures and may require urgent hospital referral.

The frequency of adverse incidents or complications when using sodium hypochlorite is difficult to determine. Many incidents tend to be locally managed with minor consequences and therefore not reported.

### What can be expected from a sodium hypochlorite accident?

If sodium hypochlorite is allowed to settle on vital tissues, it will result in a chemical burn. If the exposure is short then a minimal inflammatory response will be evoked. If the exposure is more prolonged and/or with a higher concentration solution, a more pronounced inflammatory response will occur which will lead to necrosis of the tissue affected.

#### The majority of patients experience the following:

- Pain – this can be acute and commonly with a sudden onset
- Bleeding/haemorrhaging – from the root canal
- Swelling – can occur minutes to hours after the accident (**Figure 9.1**)

**They may also experience:**

Taste of the irrigant at the back of the throat (can result in a tickly cough) – if extruded into the maxillary sinus as well as:

- Irrigant discharge from the nose – and later, acute sinusitis
- Bruising (ecchymosis) – head and neck region near the tooth
- Paraesthesia – especially if near neurovascular structures e.g. Mental foramen
- Cellulitis– this may close the ipsilateral eye
- Trismus
- Ophthalmologic symptoms – blurred vision, pain, diplopia

In exceedingly rare cases the extent of these signs and symptoms have caused life threatening sequelae causing difficulty in breathing i.e. airway obstruction due to swelling.

Each case is individual and has the potential to be minimal or extreme. Its sequelae depends on the following factors:

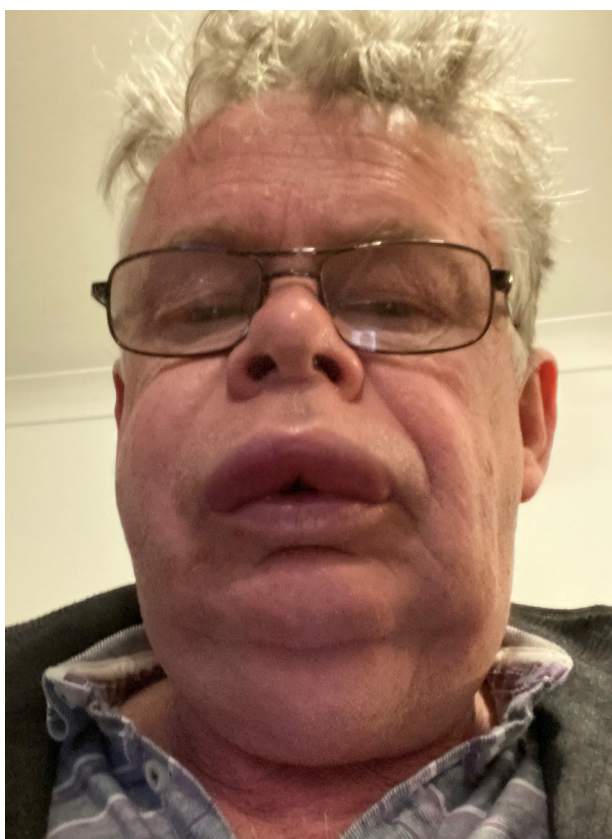- Pre-operative factors
  - Gender
  - Tooth position
  - Bone surrounding the tooth
- Intra-operative factors
  - Size of apical opening
  - Force used during irrigation
  - Concentration of sodium hypochlorite
  - Irrigant flow
  - Amount extruded
  - Syringe – bound in the canals or passive
  - Needle diameter/gauge
- Post-operative factors
  - Cellulitis

It is reported that female patients and maxillary (upper) posterior teeth appear to be more at risk than other teeth.

**How to manage it**

Attempts have been made to pool together management strategies. Farook et al (2014) tried to present a clear and precise guideline for management of patients with sodium hypochlorite (NaOCl) injury. The guideline was based on their own clinical experience and review of the literature. They categorised the treatment in relation to the severity of the injury and management in relation to the time after the injury.

A systematic review of the literature on sodium hypochlorite accidents by Guivarc'h et al (2017), confirmed that, between 1974 and 2015, there had been 52 cases presented within 40 published articles with a varied range of presentations and management strategies.



**Figure 9.1:** Extra-oral photograph of a 72-year old male showing a grossly swollen upper lip four hours after the application of sodium hypochlorite that occurred during root canal treatment of the left maxillary central incisor

**They all had the following principles of conduct in common with each other:**

- Management of pain
- Management of swelling
- Management of serious sequelae

Spencer et al (2007) recommended the use of over-the-counter analgesics and specifically, nonsteroidal anti-inflammatories (NSAIDs). The use of antibiotics is anecdotal because of the potential bacterial infection of necrotic tissue and justifies considering their provision.

**Role of local anaesthetics**

For immediate pain management, anaesthetics are a useful step. However there is some debate to suggest that infiltration may increase additional pressure that may cause more pain. Others recommend the administration of a block anaesthetic.

**Immediate management**

The dentist and nurse need to calmly explain the intended procedure and reassure the patient through each of the following steps:

1. **Immediately** irrigate the canal with saline (use water if saline is not available). This dilutes and washes out the remaining hypochlorite in the canal. It also manages the bleeding which can be diffused at this stage.
2. Dress the tooth with calcium hydroxide and a temporary filling, making sure that the occlusion is not proud, as this may add to the post-operative pain and discomfort. You will need to approach this with patience as the canal can bleed excessively and it may not be easy.
3. Pain management - more local anaesthetic and introduce analgesics immediately.
  - It is usual to advise the patient to take 1000mg paracetamol up to four times a day and 400-600mg ibuprofen up to four times a day, alternating them to provide excellent analgesia.
4. Swelling management – treat mainly with NSAIDs e.g. ibuprofen, cold compress on the first day, hot compress on the following days. Steroids may be considered if the swelling is rapid.
  - If treating a grossly infected tooth with a pre-op swelling i.e. systemic involvement - consider prescribing antibiotics, otherwise prescribe as needed during the follow up appointments. There may be necrosis of the affected tissues and there is a risk of infection
  - Prescribe antibiotics if appropriate to minimise the risk of infection to the necrotic tissue caused by the caustic burn: Amoxicillin 250-500mg three times a day. If allergic to penicillin, then Metronidazole 200-400mg
  - Use of other medication, e.g. steroids and antihistamines, may be considered if the above is not effective

Swelling may not peak until five to seven days afterwards and, although most cases resolve within two weeks of the accident, the cases with more complex injuries can last one to two months.

**Follow-up**

Make a telephone follow-up call on the same day or that evening. After that, continue daily phone calls for the first few days. Then move to once or twice each week for the proceeding few weeks until satisfied that things have resolved. Then consider obturation of the tooth.

Please note that these timeframes are for the majority of accidents. The more rare, severe cases should be followed up more often and for much longer periods. Referral to maxillo-facial colleagues should be considered if you are concerned.

## Prevention and good practice

It is important to adhere to the basics of root canal treatment including basic protection and use of aseptic techniques. Protect the eyes and clothes of patient. The steps that aid the prevention of errors in root canal treatment are:

- Routine use of a rubber dam
- Measuring files to the correct working length
- Placing stoppers for irrigation syringes 1-2mm short of working length
- The use of safe ended needles (**Figure 9.3**)
- Using index finger instead of thumb to push the syringe plunger
- Making sure the syringe is not locked into the canal by using an in and out motion whilst dispensing the irrigant
- Passive movement of the syringe to allow for the irrigant to flow around the needle back into the access cavity and be aspirated
- Asking the patient to signal to the operator or nurse if they get a bad taste during treatment
- Use lower concentration sodium hypochlorite to reduce effect of response if it occurs. It is effective between 0.5 - 5.25%

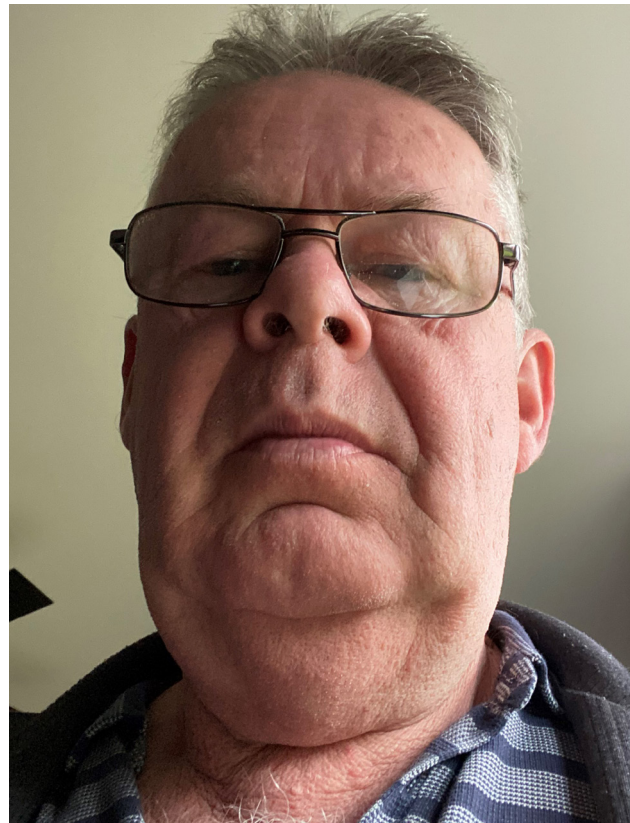## Lack of evidence

There is no clear evidence that these specific factors affect the outcome although, using information taken from laboratory based studies, it is evident that the concentration may play a significant role in the damage that can be caused to the peripheral tissues. One of the properties of sodium hypochlorite is its tissue dissolving quality which is more marked at higher concentrations; and its potential for extensive tissue damage, including necrosis.

## Medico-legal considerations

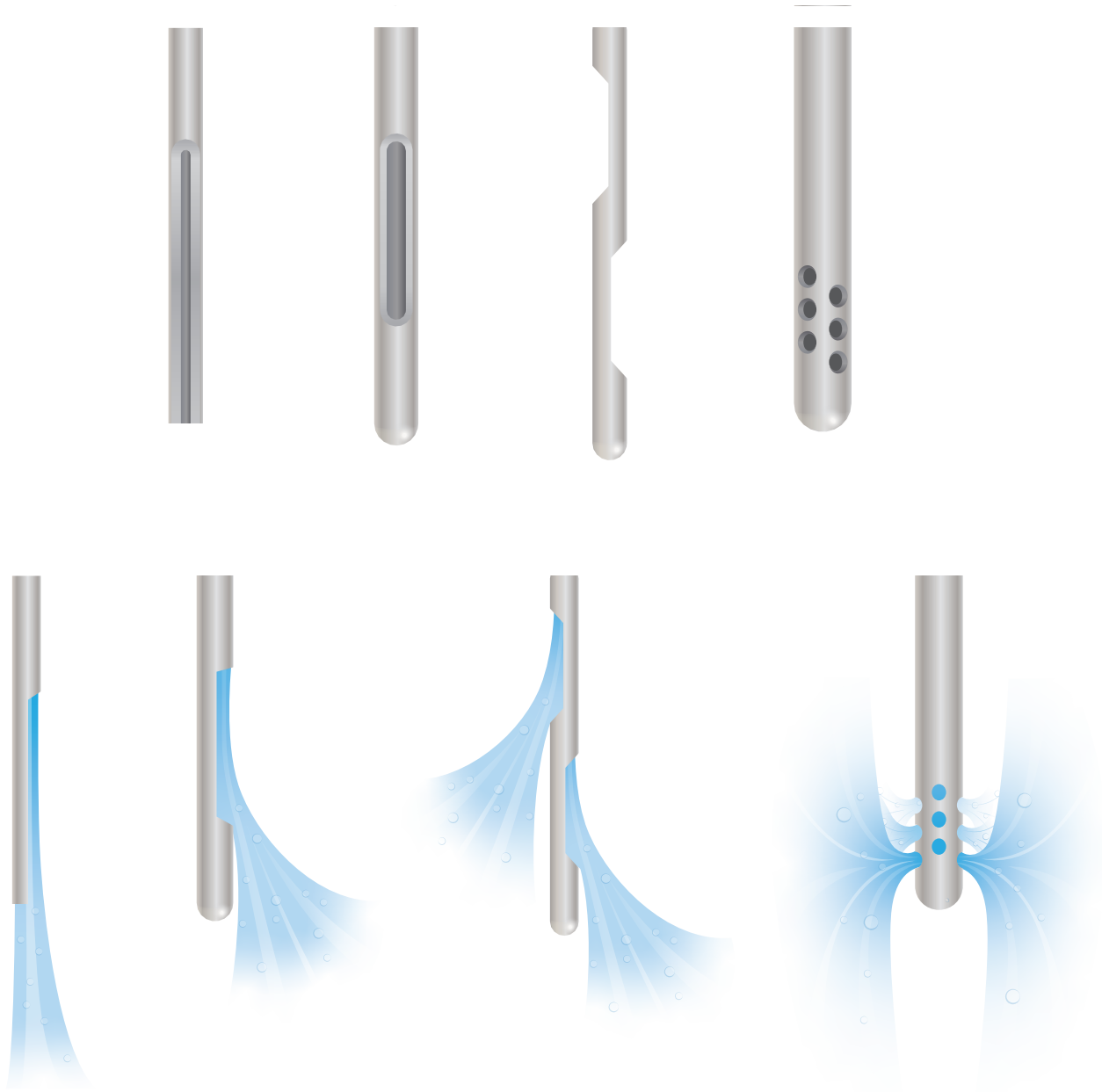
The number of claims arising from hypochlorite accidents are very few according to indemnity providers Dental Protection Limited. The cases that occur are often as a result of iatrogenic injury or misapplication of techniques e.g. lateral perforation while a coronal restoration has hindered direct access, over-preparation of apical foramen resulting in increased risk of extrusion or wedging of the irrigating syringe, resulting in extrusion. Some accidents reported by dentists to the indemnity providers are made as a precaution (incident reporting). In cases where mild symptoms resolve quickly patients often do not take action and the cases rarely progress.

The omissions that may lead to claims are in situations where there has been a failure to detect extrusion or where extrusion has been noted and the clinician has failed to refer the patient.



**Figure 9.2:** Extra-oral photograph seven days after the sodium hypochlorite accident of the patient referred to in Figure 9.1. The swelling of the upper lip has resolved





**Figure 9.3:** Various safe-ended irrigation needles that direct fluid flow laterally from the needle end and dissipate fluid pressure to help avoid rapid expulsion of the fluid in what would be an apical direction when in the canal

## Summary

Sodium hypochlorite is a very effective irrigant and can be used safely if the key preventative steps outlined above are followed.

## References

Farook SA, Shah V, Lenouvel D, Sheikh O, Sadiq Z, Cascarini L, Webb R (2014) Guidelines for management of sodium hypochlorite extrusion injuries. *British Dental Journal* 217, 679-84.

Guivarc'h M, Ordioni U, Ahmed HM, Cohen S, Catherine JH, Bukiet F (2017) Sodium Hypochlorite Accident: A Systematic Review. *Journal of Endodontics* 43, 16-24.

Shetty SR, Al-Bayati SAAF, Narayanan A, Hamed MS, Abdemagyd HAE, Shetty P (2020) Sodium hypochlorite accidents in dentistry. A systematic review of published case reports. *Stomatologija*. 22, 17-22.

Spencer HR, Ike V, Brennan PA (2007) Review: the use of sodium hypochlorite in endodontics--potential complications and their management. *British Dental Journal* 202, 555-9.



---

## **A guide to Good Endodontic Practice**

British Endodontic Society  
PO Box 707  
Gerrards Cross  
Bucks  
SL9 0XS

Tel: 01494 581 542

Website: [britishendodonticsociety.org.uk](http://britishendodonticsociety.org.uk)

---