

## Orthodontic Case Presentation (OCP–ST3)

---

In addition to the list of cases being managed by the trainee detailed in the Orthodontic Logbook Assessment Toolkit (OLAT), evidence of orthodontic diagnosis and treatment planning, longitudinal delivery of care, evaluation of the skeletal, dental and soft tissue effects of treatment and discussion of appropriate retention strategies should also undergo formative assessment during ST3.

**OCP-ST3** will consist of two detailed Orthodontic Case Presentations (OCP) selected primarily on the basis that they have produced a useful learning experience for the trainee, which should be formally presented during ST3 as a single exercise to a pair of appropriate trainers (CS/AES, ideally not directly involved in supervision of the case) to provide an opportunity for reflection on delivery of care by the trainee.

These cases can encompass a range of treatment modalities, including but not limited to interceptive treatment, orthodontic camouflage, growth modification followed by fixed appliance treatment, and multidisciplinary treatment including the management of tooth agenesis or impaction. For **OCP-ST3**, there should be an emphasis on longitudinal delivery of care and outcomes from diagnosis to completion of treatment and retention, and trainees are encouraged to liaise with their AES in terms of case selection. Indeed, it is encouraged that the AES should play a key role in the selection of cases for presentation.

This **OCP–ST3** document provides a roadmap for the information required and following formal presentation of both cases, appropriate sign-off should be undertaken by the AES within the 'Other evidence' area of the ISCP site and validation at the ARCP.

# CASE HISTORY TEMPLATE

CASE NUMBER: [N]

PATIENT'S INITIALS: [I.I]

CASE SUMMARY

[A brief description of the case, maximum 100 words]

SECTION 1. PRE-TREATMENT ASSESSMENT

PATIENT DETAILS

**Initials:**

**Sex:**

**Date of birth:**

**Age at start of treatment:**

PATIENT'S COMPLAINT/S

RELEVANT MEDICAL HISTORY

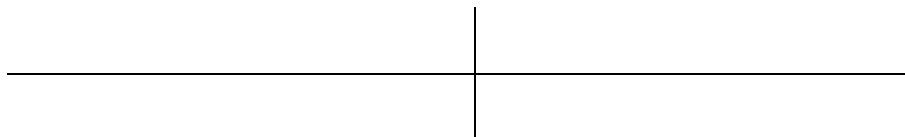
CLINICAL EXAMINATION: EXTRA-ORAL FEATURES

CLINICAL EXAMINATION: INTRA-ORAL FEATURES

Soft tissues:

Oral hygiene:

Erupted teeth present:



General dental condition:

## **OCP FOR ORTHODONTIC ST3**

---

CROWDING / SPACING

Maxillary arch:

Mandibular arch:

OCCLUSAL FEATURES

**Incisor relationship:**

**Overjet (mm):**

**Overbite:**

**Centrelines:**

**Left buccal segment  
relationship:**

**Right buccal segment  
relationship:**

**Crossbites:**

**Displacements:**

**Other occlusal features:**

**OCP FOR ORTHODONTIC ST3**

---

PRE-TREATMENT PHOTOGRAPHS: EXTRA-ORAL

[Insert frontal and profile photographs here]

**OCP FOR ORTHODONTIC ST3**

---

PRE-TREATMENT PHOTOGRAPHS: INTRA-ORAL

[Insert frontal, right and left buccal, upper and lower occlusal photographs here]

**OCP FOR ORTHODONTIC ST3**

---

PRE-TREATMENT PHOTOGRAPHS: OTHER RELEVANT VIEWS

[Insert any other relevant views here]

**OCP FOR ORTHODONTIC ST3**

---

PRE-TREATMENT PHOTOGRAPHS: STUDY MODEL PHOTOGRAPHS OR 3D SCANS

[Insert frontal, right and left buccal, upper and lower occlusal images here]



**OCP FOR ORTHODONTIC ST3**

---

GENERAL RADIOGRAPHIC EXAMINATION

Pre-treatment radiographs taken:

Unerupted teeth:

--	--

Teeth absent:

--	--

Teeth of poor prognosis:

--	--

Other relevant radiographic findings:

PRE-TREATMENT RADIOGRAPHS

[Insert prints of radiographs or duplicate film radiographs here]

OTHER SPECIAL TESTS / ANALYSES

[This is optional. Present details and results of any other tests or measurements, which are available and which contribute to the assessment of the case]

## **OCP FOR ORTHODONTIC ST3**

---

### PRE-TREATMENT CEPHALOMETRIC TRACING:

[Attach cephalometric tracing here. The tracing should be either 1) provided on acetate to scale so that the tracing can be checked directly over the cephalometric radiograph; or 2) provided digitally over the cephalometric radiograph so the tracing can be assessed.]

## OCP FOR ORTHODONTIC ST3

---

### PRE-TREATMENT CEPHALOMETRIC ANALYSIS

VARIABLE	PRETREATMENT	NORMAL
<b>SNA</b>		82° ± 3
<b>SNB</b>		79° ± 3
<b>ANB</b>		3° ± 1
<b>SN to maxillary plane</b>		8° ± 3
<b>Wits appraisal</b>		0 mm
<b>Upper incisor to maxillary plane angle</b>		108° ± 5
<b>Lower incisor to mandibular plane angle</b>		92° ± 5
<b>Interincisal angle</b>		133° ± 10
<b>Maxillary mandibular planes angle</b>		27° ± 5
<b>Upper anterior face height</b>		
<b>Lower anterior face height</b>		
<b>Face height ratio</b>		55%
<b>Lower incisor to APo line</b>		0-2 mm
<b>Lower lip to Ricketts E Plane</b>		-2 mm

---

#### Sources of normal values:

Houston WJB, Stephens CD & Tulley WJ (1992) A textbook of Orthodontics. Wright, Oxford  
Cobourne MT, DiBiase AT (2024) Handbook of Orthodontics. 3<sup>rd</sup> Edition. Elsevier

## **OCP FOR ORTHODONTIC ST3**

---

### ADDITIONAL CEPHALOMETRIC ANALYSIS (OPTIONAL)

[Where an additional analysis is used, provide clear definitions of the measurements together with means and standard deviations]

### INTERPRETATION

DIAGNOSTIC SUMMARY

PROBLEM LIST

[Add as few or as many as are appropriate to the case]

- 1.
- 2.
- 3.
- 4.
- 5.
- 6.

AIMS AND OBJECTIVES OF TREATMENT

[Add as few or as many as are appropriate to the case]

- 1.
- 2.
- 3.
- 4.
- 5.
- 6.

TREATMENT PLAN

Extractions:

Appliances:

Special anchorage requirements:

Minor adjunctive surgery:

Major adjunctive surgery:

Additional dental treatment:

Proposed retention strategy:

Prognosis for stability:



COMPUTER PREDICTIONS

[Optional: Where cases are presented which involve orthognathic surgery, output from computerised planning systems may be included on these two pages. Alternatively, these pages may be used for additional mid-treatment photographs demonstrating treatment mechanics in SECTION 2]

COMPUTER PREDICTIONS

**SECTION 2. TREATMENT**

**TREATMENT PROGRESS**

**Start of active treatment:**

**Age at start of active treatment:**

**End of active treatment:**

**Age at end of active treatment:**

**End of retention:**

**KEY STAGES IN TREATMENT PROGRESS**

[Provide a brief summary of approximately 8 – 10 key stages in the treatment sequence]

---

<b>DATE</b>	<b>STAGE</b>
1.	
2.	
3.	
4.	
5.	
6.	
7.	
8.	
9.	
10.	

---

KEY STAGES IN TREATMENT PROGRESS (CONTINUED)

MID-TREATMENT PHOTOGRAPHS:

[Insert any relevant photographs which illustrate treatment mechanics at any key stages of interest]

MID-TREATMENT RADIOGRAPHS:

MID-TREATMENT CEPHALOMETRIC TRACING

## OCP FOR ORTHODONTIC ST3

---

### MID-TREATMENT CEPHALOMETRIC VALUES

VARIABLE	PRE-TREATMENT	MID - TREATMENT	CHANGE
SNA			
SNB			
ANB			
SN to maxillary plane			
Wits appraisal			
Upper incisor to maxillary plane angle			
Lower incisor to mandibular plane angle			
Interincisal angle			
MM angle			
Upper anterior face height			
Lower anterior face height			
Face height ratio			
Lower incisor to APo line			
Lower lip to Ricketts E Plane			



## SECTION 3. POST-TREATMENT ASSESSMENT

### OCCLUSAL FEATURES

**Incisor relationship:**

**Overjet (mm):**

**Overbite:**

**Centrelines:**

**Left buccal segment  
relationship:**

**Right buccal segment  
relationship:**

**Crossbites:**

**Displacements:**

**Functional occlusal features**

**Other occlusal features:**

COMPLICATIONS ENCOUNTERED DURING TREATMENT:

## OCP FOR ORTHODONTIC ST3

---

### OCCLUSAL INDICES

INDEX	PARAMETER	VALUE
<b>Index of Treatment Need (IOTN)</b>		
<b>Dental Health Component</b>	Start	
	Finish	
<b>Aesthetic Component</b>	Start	
	Finish	
<b>Peer Assessment Rating (PAR)</b>		
	Start	
	Finish	
	Change	
	% Change	
<b>Other</b>		

### RADIOGRAPHS TAKEN TOWARDS / AT END OF TREATMENT

Radiographs taken:

Relevant findings:

POST-TREATMENT RADIOGRAPHS

[Insert prints of radiographs or duplicate film radiographs here]

**OCP FOR ORTHODONTIC ST3**

---

POST-TREATMENT CEPHALOMETRIC TRACING: (Where appropriate)

[Insert cephalometric tracing]

**OCP FOR ORTHODONTIC ST3**

---

POST- TREATMENT CEPHALOMETRIC ASSESSMENT (where appropriate)

<b>VARIABLE</b>	<b>PRE-TREATMENT</b>	<b>POST- TREATMENT</b>	<b>CHANGE</b>
<b>SNA</b>			
<b>SNB</b>			
<b>ANB</b>			
<b>SN to maxillary plane</b>			
<b>Wits appraisal</b>			
<b>Upper incisor to maxillary plane angle</b>			
<b>Lower incisor to mandibular plane angle</b>			
<b>Interincisal angle</b>			
<b>MM angle</b>			
<b>Upper anterior face height</b>			
<b>Lower anterior face height</b>			
<b>Face height ratio</b>			
<b>Lower incisor to APo line</b>			
<b>Lower lip to Ricketts E Plane</b>			

ADDITIONAL ANALYSIS (OPTIONAL)

INTERPRETATION OF CEPHALOMETRIC CHANGES

CEPHALOMETRIC SUPERIMPOSITION

[Overall superimposition on the anterior cranial base (rather than on the Sella-Nasion line)]

CEPHALOMETRIC SUPERIMPOSITION

Maxillary and mandibular regional superimpositions.

[The stable anatomical structures of the mandible are: 1) The anterior contour of the chin; 2) The inner cortical structure at the inferior border of the symphysis; 3) Trabecular structures in the symphysis; 4) Trabecular structures related to the mandibular canal; 5) The lower contour of a molar tooth germ from the time mineralisation of the crown is visible until the roots begin to form]

[The stable structure associated with the maxillary complex is the anterior contour of the zygomatic process]



POST-TREATMENT PHOTOGRAPHS: EXTRA-ORAL

[Insert frontal and profile photographs here]

POST-TREATMENT PHOTOGRAPHS: INTRA-ORAL

[Insert frontal, right and left buccal, upper and lower occlusal images here]

**OCP FOR ORTHODONTIC ST3**

---

POST-TREATMENT PHOTOGRAPHS: STUDY MODEL PHOTOGRAPHS OR 3D SCANS

[Insert frontal, right and left buccal, upper and lower occlusal images here]

**SECTION 4.**

[No more than 2 pages Arial font 11]

a) RATIONALE FOR TREATMENT

b) CRITIQUE

Learning outcomes section: Trainees are encouraged to include evidence they have achieved the learning outcomes expected of them during their training. A list of outcomes and evidence can be included here: